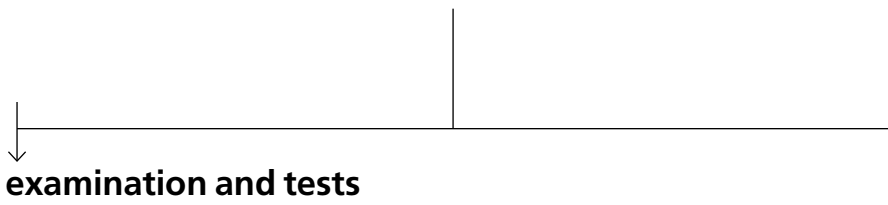


Adult with dizzy spells

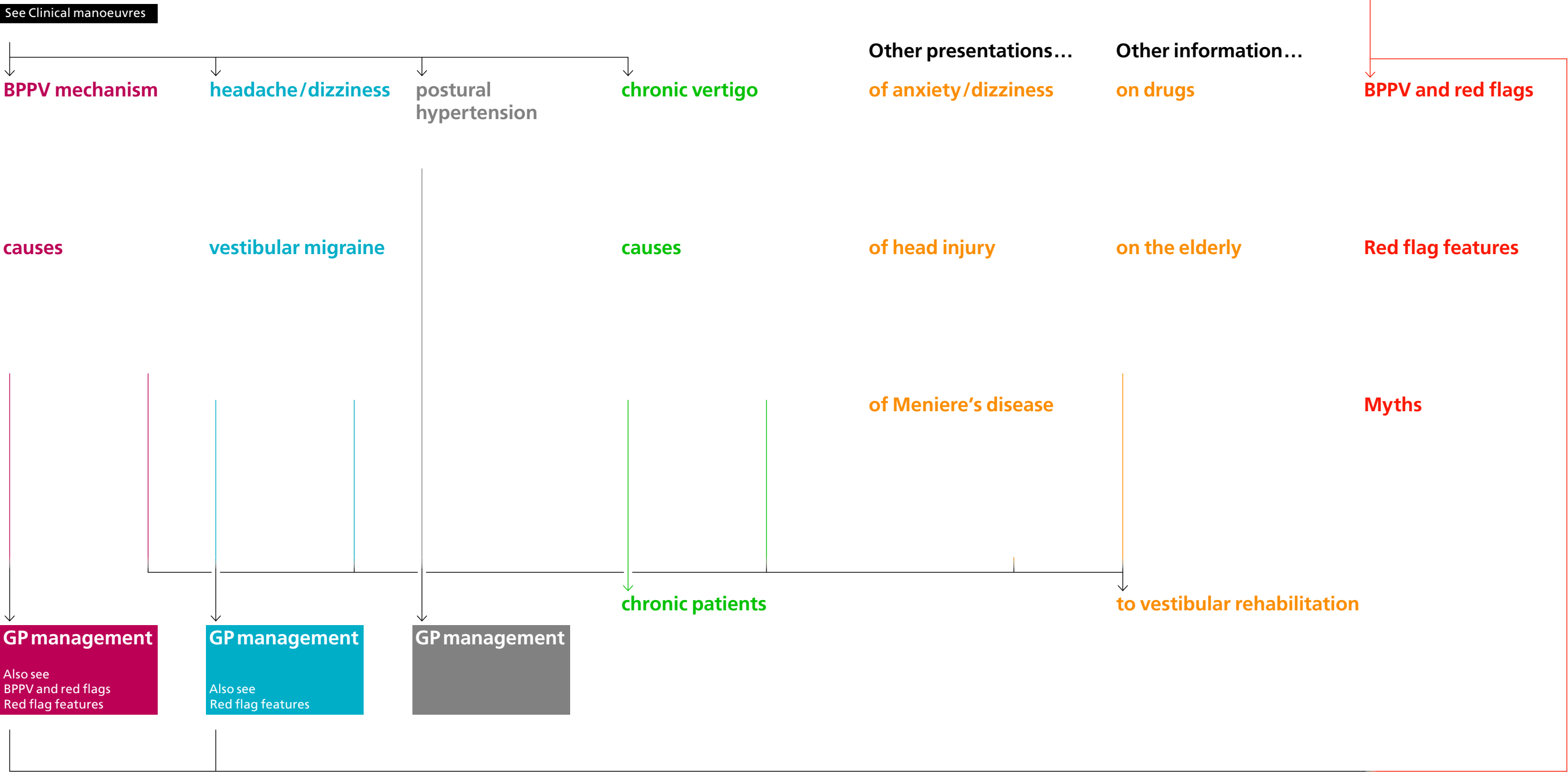
Problem-specific video guides to the diagnosis and the management of dizziness in adults

Introduction... to rebalancing referral patterns

Understanding... dizziness vs imbalance dizziness intensity tinnitus, hearing loss and aural fullness Imbalance and red flags Find out more ...



Diagnosing and treating...



Referring...

Clinical manoeuvres... and the elderly

for examination and tests and BPPV

Dizziness vs imbalance

- Is it dizziness? Is there an element of illusory self-motion or illusory environmental motion? Either one or both then element of dizziness
- Often confused by patients describing dizziness as imbalance – the sensation you might fall
- Imbalance only occurs on standing
- If patient has problems sitting or lying like to be dizzy. Could have both
- Key question: 'Do you feel dizzy when you turn over in bed?'. If yes could be BPPV but not postural hypotension

History taking – tips in acute dizziness

Make sure that both you and the patient are speaking the same language

Do they really mean dizziness?

Define the symptoms to the patient and then ask them if that is what they really mean.

– Dizziness: An illusion of self-motion when in fact one is stationary. (Hence, dizziness is thus also present without vision.)

– Oscillopsia: An illusion of visual world motion when in fact the world is stationary either in absolute terms or relative to the observer. (Oscillopsia can thus only occur when vision of the environment is available.) Oscillopsia is sometimes confused with dizziness although dizziness and oscillopsia may occur together.

– Oscillopsia is always due to a nystagmus.

Obtain a description of the dizziness symptoms:

– Rotatory: Horizontal ‘merry-go-round’ (synonymous with vertigo) or vertical plane ‘head over heels’.

– Rocking: ‘Like a boat’.

– Linear: Horizontal or vertical plane (including falling).

– If there is no illusory self-motion then there is no dizziness

– Elderly patients may lose the perception of dizziness so you need to screen for common causes of imbalance (postural hypotension, BPPV, migraine).

Continued from previous page

What exactly is the duration of acute attack?

– Subjective recall of time is highly variable, particularly at the lower end of the scale (i.e. seconds to minutes). Patients with BPPV may describe that their dizziness lasts 'two minutes'. We suggest counting out aloud and asking the patient to say 'stop' when the recalled duration of intense spinning dizziness has abated. Time and again patients who describe their dizziness as lasting two minutes will say 'stop' after a count of 7 or 8 (compared to 120 seconds!).

– Continuous or prolonged symptoms: Patients after an episode of BPPV can feel destabilised for minutes, hours or even an entire day. If the clinician is not careful they may obtain a history of prolonged dizziness and so lead one away from a BPPV diagnosis. The prolonged symptoms will not be violent spinning vertigo but something more non-specific. Hence it cannot be over-emphasised that the clinician must be descriptive in obtaining a patient's dizzy symptoms; e.g. 'What does it feel like? Spinning, rocking etc.' and one will not confuse this continuous 'dizziness' with that of the acute vertiginous attack.

It is recommended that the GP screen for the three common causes of dizziness (postural hypotension, BPPV and migraine) and imbalance in all patients.

Background chronic symptoms

– Patients presenting with acute vertigo may have a long history of recurrent vertigo. Such patients may develop chronic and persisting symptoms apparently unrelated to acute vertiginous attacks. These symptoms are often situational (e.g. I feel unsteady in open spaces) and thus may lead the clinician to consider a functional disorder.

Such maladaptive symptoms, which are exacerbated by visual motion, are relatively common in patients with recurrent vertigo whatever the aetiology. Although usually induced dizziness symptoms do not point to any specific diagnosis, clinicians should be aware of them so that they are not lead astray.

Screen for the common causes of dizziness and refer if negative.

Continued from previous page

Key questions

1 What are the details of first episode of symptoms – whether patient felt light headed or if the surroundings were spinning?

2 Any other symptoms – hearing loss, tinnitus, nausea, vomiting or fullness in the ear?

3 How often did the symptoms occur and how long did they last?

4 Are the symptoms affecting daily activities – able to walk during an episode of vertigo?

5 Does anything trigger the symptoms or makes them worse – moving the head in a particular direction?

6 What makes the symptoms better?

Imbalance and red flag

- Acute onset imbalance or step change in balance function - stroke.
- For stroke assess tandem gait. Patient will fall to the side of the brain lesion

Chronic vertigo

Causes

- Failure to treat underlying causes
- Inappropriate drugs used to treat dizziness
- Maladaptive response to untreated dizziness

First step

Look for underlying diagnosis: BPPV, migraine

Second step

Treat the underlying diagnosis

Third step

Refer to vestibular rehabilitation services

Referring chronic patients

- Screen: for BPPV, cardiac dysrhythmia using an ECG and postural hypotension and ask about migraine symptoms
- Chronic symptoms: head motion intolerance, visual motion intolerance
- Only refer to rehabilitation once a definitive diagnosis is established. The therapist's treatment plan varies according to the diagnosis. The therapist's role does not include making a diagnosis.

Chronic vertigo causes

- Missed diagnosis of any vestibular condition
- BPPV
- Migraine

Incorrect treatment of vestibular conditions
(linked with missed or mis-diagnosis)

- chronic treatment with Prochlorperazine
- Betahistine for non-Meniere's disease diagnosis

Inappropriate use of exercises:

- Brandt Daroff exercises for non BPPV e.g. migraine (Brandt Daroff exercises are used for used for BPPV)

Cawthorne-Cooksey exercises for BPPV.
(Cawthorne-Cooksey exercises are used for vestibular rehabilitation)

BPPV mechanism

Commonest cause of vertigo

Crystals form in the semi-circular canals. Crystals are heavier (denser) than the endolymph and so sink under gravity following head movement. The movement of the crystal stimulates the receptors in the peripheral vestibular organ leading to a transient nystagmus, imbalance and a sensation of vertigo.

In the elderly, the perception of vertigo may be blunted and they may fall over without complaining of vertigo. 100% of patients with imbalance should be screened for BPPV, using the Hallpike manoeuvre.

Diagnosis - Hallpike

Treatment - Epley or Semont

Key question: 'When you turn over in bed do you feel dizzy?' Yes for BPPV but no for postural hypotension

BPPV and red flags

- Post Hallpike manoeuvre nystagmus persists (usually lasts 5–15 seconds)
- BPPV that does not respond to repositioning manoeuvre

Headache and dizziness

Recurrent

Likely to be vestibular migraine

First presentation

Particularly occipital headache, and onset vertigo with or without nystagmus – stroke must be excluded

Red flags: headache & vertigo

- Hyper acute onset vertigo
- First presentation headache
- Valsalva manoeuvre precipitates vertigo onset
- Gait ataxia

Vestibular migraine

- Episodic dizziness with at least some episodes associated with headache: photophobia, phonophobia
- With or without motion intolerance
- Complete recovery between episodes

Red flag for referral

- Not typical episodic pattern e.g. progressive pattern
- Current treatment not successful

Management

- Education patient of disorder – describing what it is
- Lifestyle advice: regular sleep, eating, avoiding caffeine, alcohol
- Dietary – little evidence
- Acute relief and prophylaxis (migraine drugs
Propanolol, Pizotifen,
Amitriptyline, Sodium Valproate,
Topiramate

Rehabilitation

- Consider for disequilibrium, head motion intolerance, visual motions intolerance. See Vestibular rehabilitation - but only once migraine is controlled by lifestyle, with or without drug therapy

Meniere's disease

- Uncommon cause of vertigo
- Episodic unilateral auditory symptoms: aural fullness, tinnitus and hearing loss with
- Episodes of vertigo: develops over minutes-hours, associated with vomiting and incapacitating.
- Early stages – complete recovery between episodes. Prognosis variable: for some patients it settles down quickly, others the hearing gets progressively worse, others vertigo gets worse.
- Initial diagnosis should be made in a balance clinic. It is uncommon and over diagnosed.

Should be referred for:

- Specialist diagnosis – other conditions can mimic Meniere's.

Management:

- Medically – acute relief if symptoms infrequent
- Betahistine
- Diuretics
- Low salt diet
- Intratympanic - steroids
- Surgery
- Auditory rehabilitation – tinnitus and hearing loss

Rehabilitation:

- Early stages often get complete recovery so rehabilitation not so helpful
- Useful for patients who experience between attacks symptoms of disequilibrium, imbalance, head motion intolerance, visual motions intolerance
- Rehabilitation is most useful once there are no further acute attacks.

Anxiety and dizziness

- Uncommon primary cause
- Look for underlying vestibular diagnosis and treat (Screen for postural hypotension, BPPV and migraine)
- Referral to balance clinic –services to treat vestibular and psychological components

Head injury

Common causes of dizziness and imbalance in head injury and concussion:

- 1 BPPV
- 2 Migraine
- 3 Vestibular nerve damage (e.g. fracture of petrous temporal bone) 4

In the acute setting (typically accompanied by hearing loss on that side) the commonest problem is a centrally-mediated gait ataxia. This can be helped with gait physiotherapy.

It is typical for head injury patients to have multiple causes of imbalance and dizziness in the same patient.

Drugs – Stemetil and Betahistine

Prochlorperazine (Stemetil) and Betahistine (Serc)

Prochlorperazine should only be used as a short course (2-3 days) for acute attacks. Chronic treatment with Prochlorperazine should never be used in dizzy patients. In this case refer to a balance clinic for a definitive diagnosis and treatment plan.

Primary care physicians should not start Betahistine without first consulting with a balance clinic.

Betahistine is only indicated in Meniere's disease.

Given that Meniere's disease is uncommon it is unlikely, but not impossible, that your patient has Meniere's. Migraine is the more common diagnosis and can superficially mimic Meniere's.

Always refer patients who you think might have Meniere's disease. See Find Out More on page 1.

Vestibular rehabilitation

Exercises based on the understanding of vestibular physiology and mechanisms underlying compensation to induced brain plasticity to improve subjective symptoms of dizziness, postural induced, gait instability and visual induced dizziness.

Refer

- BPPV treated but still experiencing maladaptive symptoms
- Vestibular neuritis, labyrinthitis. This diagnosis must be secured following an acute hospital referral or balance clinic assessment for late presentations.
- Vestibular migraine
- Meniere's disease

GP actions

- GP should secure a diagnosis before referral
- Start any treatment e.g. drug prophylaxis for migraine

Ideally the rehabilitation service should provide an information leaflet explaining the following:

- Inform patient about vestibular rehabilitation (preparation and support):
 - Understand it is process, not a single set of exercises but a progression based on the individuals impairment.
 - Could initially feel worse before it gets better 1–10 days, notice improvements at about 3 weeks.
 - Could last 3-6 months.
- Not a linear progression progress does fluctuate.
- Outcomes excellent – 80% patients improve, return to work and recreational activities

- Factors affecting outcomes:
 - Compliance with programme – completing exercises
 - Medication
 - Anxiety or depression
 - Consideration of Tai Chi/yoga – as an adjunct.
 - Return to recreational activities gradually and ideally concurrently when able.
- Support for patients that feel dizzy but do not fall.
- Support for patients that fall. Falls clinics should have strong links with vestibular clinics and vestibular rehabilitation services

Red flag features

Headache

40% posterior circulation stroke

Gait ataxia

May be only non-vertiginous manifestation of cerebellar stroke

Hyperacute onset

Suggests vascular origin

Vertigo and hearing loss

AICA or urgent ENT problem

Prolonged symptoms (greater than 4 days)

Floor of fourth ventricle problem

Myths

- Ear infections and vertigo
- Vestibular basal insufficiency
- Cervicogenic dizziness
- Recurrent labyrinthitis

Postural hypotension

Lie the patient down on the examination couch for five minutes.

The patient's legs must be at the same level as their torso.

Measure the blood pressure with the patient lying on the couch.

Stand the patient up and measure the blood pressure at one minute and three minutes.

You can have the patient leaning against the edge of the couch to maintain their balance.

A drop in systolic blood pressure greater than or equal to 20mmHg is abnormal.

A drop of greater than or equal to 10mmHg for diastolic blood pressure is abnormal.

List of the videos

1

Rebalancing referral patterns

Common presentations GPs should diagnose and treat successfully – cardiovascular causes of recurrent dizziness, postural hypotension, BPPV and migraine. Aware of presentations should seek advice/ refer – acute first onset vertigo: labyrinthitis, vestibular migraine and stroke). Aim to rebalance referral patterns between GP and specialist services.

2

Dizziness vs imbalance

Distinguishing between the two. The key question to ask.

3

Imbalance and red flags

Recent onset imbalance – change in their ability to walk. Elderly patients. Assessment of imbalance.

4

Dizziness intensity and the neurological anatomy of vertigo sensation

Intensity and diagnosis. Anatomy: ear, nerve, brain stem, cerebral cortex.

5

Tinnitus, hearing loss and aural fullness

Meniere's disease, vestibular migraine and red flag – brain stem stroke. First acute vertigo with hearing loss should refer for specialist opinion.

6

Examination and tests

ECG, postural blood pressure, Hallpike.

7

Chronic vertigo

Untreated underlying causes, drugs, maladaptive responses and rehabilitation.

8

When to refer chronic patients

Rule out common causes. Refer. Treat cause before rehabilitation.

9

Causes of recurrent vertigo

Common causes: BPPV and migraine. Untreated or incorrect diagnosis leads to chronic condition. Apparent recurrent labyrinthitis.

Continued from previous page

10

BPPV mechanism

What causes it. Commonest cause of vertigo. Imbalance, nystagmus, perception. Treatment. The elderly. The key question to distinguish between BPPV and postural hypotension.

11

Epidemiology and causes of BPPV

All age groups. No prior event but some triggers: labyrinthitis and head injury.

12

When to refer BPPV and red flag

Atypical nystagmus, not responding to treatment. Difficulty in distinguishing between peripheral and central vestibular nystagmus.

13

Position testing and the elderly

Hallpike – see linked video. Adjustment to prevent twisting the neck.

14

Headache and dizziness

First presentation or recurrent. First acute presentation vertigo and headache – red flag refer in case it is a stroke.

15

Vestibular migraine

Vestibular symptoms, recurrent and episodic, manage in primary care, refer if migraine pattern differs from recurrent/episodic, not responding to treatment. Education of patient, lifestyle, analgesics, prophylaxis, prognosis and rehabilitation.

16

Meniere's disease

Episodic, symptoms, recovery, prognosis. See drugs – Betahistine.

17

Anxiety as a cause of dizziness

Uncommon as primary cause of vertigo. Vestibular dysfunction common cause of anxiety. Balance clinic – vestibular diagnosis, treatment and psychological support.

18

Head injury

Balance dysfunction common. Acute: BPPV, gait disorders, vestibular transection – hearing loss, migraine. Multiple vestibular diagnosis. Treatment – step by step approach.

Continued from previous page

19

Dizziness and the elderly

Not describe vertigo well, multiple causes. Tests and examinations.

20

Drugs – Stemetil and Betahistine

Correct diagnosis, not treat chronically with vestibular sedatives, side effects. Betahistine – use for Meniere's disease.

21

Vestibular rehabilitation

What it is. Types of patient to refer. Treat symptoms of dizziness, need clear diagnosis and to have started treatment before referral, patient education, duration, outcomes, recreational activity.

22

Red flags

Acute onset vertigo, gait ataxia, first headache and vertigo, hearing loss and vertigo.

23

Myths

Ear infection, vertebrobasilar insufficiency, cervicogenic dizziness, recurrent labyrinthitis.

Acknowledgements

Video content created by
London Neuroscience Strategic Clinical Network shared learning working group
July 2015.

Dr Barry Seemungal, Consultant neurologist, Imperial College Healthcare NHS Trust
Dr Nassif Mansour, GP, Kingston
Dr Louisa Murdin, Consultant Audio Vestibular Physician
Dr Marousa Pavlou, Lecturer in Physiotherapy
Dr Nick Losseff, Consultant neurologist, NHNN (UCLH)

Version 1.0
September 2015

REVIEW

Pract Neurol 2010; 10: 129–139

Chronic dizziness: a practical approach

A M Bronstein,¹ T Lempert,² B M Seemungal¹

Patients with chronic dizziness pose a particular challenge to the clinician, partly because their symptoms correlate poorly with standard vestibular tests; so a 'test and think later' approach is likely to lead to diagnostic confusion rather than clarity. Rather, a meticulous clinical assessment is required. Here our approach to the chronic dizzy patient is described with an emphasis on treating the patient's symptoms.

INTRODUCTION

Bryan Matthews' famous quote "There can be few physicians so dedicated to their art that they do not experience a slight decline in spirits on learning that their patient's complaint is of giddiness" still rings true to many neurologists facing long term dizzy patients.¹ We will try to dispel this prejudice.

Chronic dizziness is reported by 0.3% of the adult population² and accounts for about 10% of new patients seen in a general neurology clinic.³ The neurologist is often called on after the chronic dizzy patient has already seen another specialist (eg, ear, nose and throat) and hence they will have had many investigations already, including scans, hearing and maybe even vestibular function tests. The question then becomes 'what can the neurologist add to this situation?' The answer should be an accurate diagnosis and appropriate treatment despite multiple tests. This is because, as ever, an accurate history and examination is what is required. Specialist investigations come a distant second to the clinical assessment and only help to refine the diagnosis.

MAKING A START IN THE PATIENT WITH CHRONIC DIZZINESS

The first step is to define the current symptoms; here it is critical to establish exactly what the patient means by 'dizziness'. Clarify if there is a sensation of self-motion, and if so its nature:

- Spinning, like a merry-go-round?
- Rocking, like-a-boat?
- Linear as in falling or thrusting?
- Tilting?
- Floating (more non-specific)?

Alternatively, there may be a feeling of disequilibrium rather than dizziness—that is, there is no problem with an abnormal self-motion sensation but rather patients feel unsteady on their feet or even as if they are walking on a mattress.

While the description of the *current* symptom is important, it is also important to know the *evolution* of the symptoms—that is, how the symptoms started and how they have changed? This evolution can follow one of three patterns (figure 1):

- the patient who started with one or more attacks of rotational vertigo

¹Neuro-otology Unit, Centre for Neuroscience and Mental Health, Imperial College London, Charing Cross Hospital, London, UK

²Neurology Department, Schlosspark Klinik, Berlin, Germany

Correspondence to

Professor A M Bronstein, Neuro-otology Unit, Centre for Neuroscience and Mental Health, Imperial College London, Charing Cross Hospital, London W6 8RF, UK; a.bronstein@imperial.ac.uk

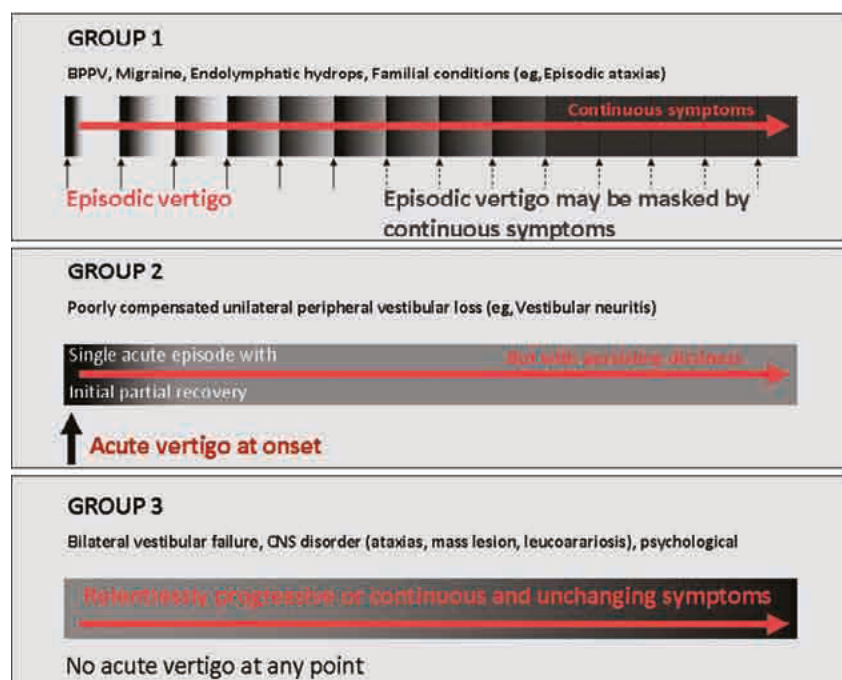


Figure 1

Three pathways that patients may follow and thus develop chronic dizziness. Episodic vertigo (eg, migraine, Ménière's disease, benign paroxysmal positional vertigo (BPPV)) gradually leading to chronic dizziness (group 1), a single attack of vertigo (typically vestibular neuritis) with some initial recovery but many residual symptoms (group 2) and chronic, slowly progressive conditions (eg, polyneuropathies, idiopathic bilateral vestibular failure) (group 3).

BOX 1 Factors which may interfere with recovery following vestibular lesions (slightly modified from Bronstein and Lempert³¹)

- Age
- Active migraine
- Brain lesions (particularly cerebellar)
- Peripheral neuropathy
- Visual disorders
 - Reduced visual acuity
 - Modified optics (eg, cataract operation)
 - Strabismus
- Factors reducing head movements (eg, neck stiffness)
- Psychosocial problems
- Medical interventions
 - Insufficient/inadequate counselling
 - Antivertiginous drugs
 - Tranquilisers
- Lack of mobility
 - Orthopaedic (eg, hip arthritis)
 - Excessive bed rest or patient advised not to move
 - Fear (eg, of vertigo or falling)
 - Avoidance of symptom provoking situations

THE CHRONIC DIZZY PATIENT WITH A HISTORY OF ONE OR MORE ATTACKS OF VERTIGO

Patients in this category report one or more previous vertigo attacks:

- **Vestibular neuritis:** there will be a single but disabling attack of vertigo lasting for a few days.
- **Benign paroxysmal positional vertigo (BPPV):** multiple brief episodes (lasting seconds) of rotational vertigo on looking up or lying down and turning over in bed. Patients can have recurrent, undiagnosed and untreated BPPV for decades.
- **Migrainous vertigo:** recurrent attacks of vertigo lasting from minutes to a few days (usually hours). Look for typical accompanying migrainous features such as headache, photophobia, visual auras, etc.⁴ There are no interictal abnormalities.
- **Ménière's disease** (endolymphatic hydrops): typical attacks of auditory distortion, auditory fullness, tinnitus and vertigo. There is eventual progressive unilateral audiovestibular failure.⁵

WHY DO SOME PATIENTS NOT RECOVER FULLY AFTER ONE OR MORE EPISODES OF VERTIGO?

We suspect this is the consequence of incomplete vestibular compensation (box 1). Vestibular compensation can be most easily observed in the nystagmic response following vestibular neuritis (figure 2 shows horizontal eye movement recordings following a permanent unilateral peripheral vestibular lesion). The top trace shows massive nystagmus. The bottom trace shows that a month later there is virtually no nystagmus. The brainstem vestibular nuclei and cerebellum play key roles in the resolution of vestibular nystagmus after an acute peripheral vestibular lesion.⁶⁻⁸ Animal studies allude to the potential inimical influences on the brainstem processes of vestibular compensation—for example, disturbances of visual input (visual cortex ablation in primates impairs compensation),⁹ and excessive stress, physical or emotional, by its effect on corticosteroid activity.^{10 11} Our own empirical observation suggests that active migraine retards vestibular compensation and we have a low threshold for using migraine prophylaxis in patients requiring vestibular rehabilitation.

- the patient with a persisting history of disequilibrium
- the patient with neither of these.

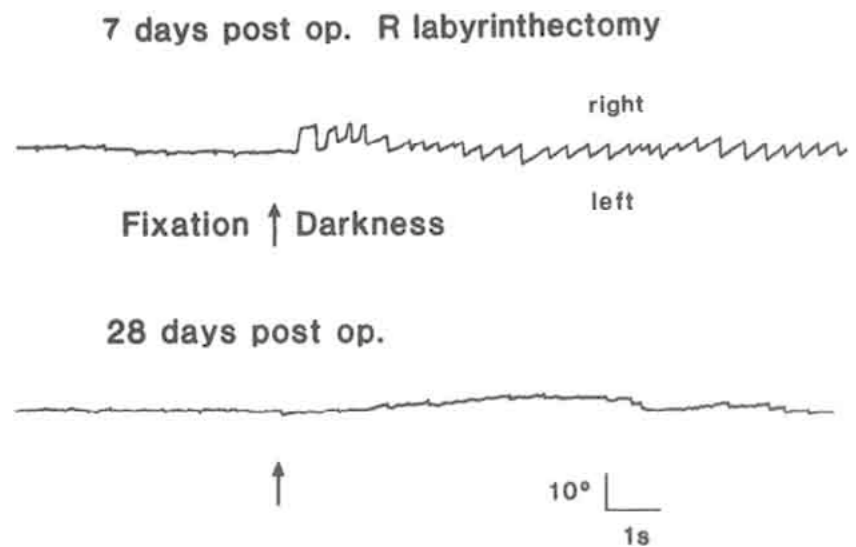
Recent evidence¹² suggests that the vestibular mechanisms that control eye movements and patients' symptoms are mediated by two separate but linked systems: one brainstem and the other a perceptual (presumably cortical) system. Thus in acute vertigo, eye movements and perception are strongly coupled whereas in chronic vertigo eye movements correlate poorly with symptoms.^{13–14} Although multiple cortical loci that mediate vestibular perception have been identified,^{15–17} the basic mechanisms underlying vestibular cortical function are poorly understood. Thus we know much less about the factors which may influence the process of vestibular compensation at the cortical level compared with the brainstem level.

Whatever the cause of failure to compensate, anxiety and/or depression are associated with long term symptoms and disability.¹⁸ It is of course plausible that depression can directly interfere with vestibular compensation (or indirectly by the impact of chronically elevated cortisol on brainstem compensation at least).¹⁰ Furthermore, as with any other chronic disease, psychological adjustment to protracted or recurrent vestibular dysfunction may play a critical role.¹⁹ In one study, comorbid anxiety and depression were found in 57% of Ménière's and 65% of vestibular migraine patients but only in 22% of those with vestibular neuritis and 15% with BPPV.²⁰ The entanglement of chronic vestibular migraine with anxiety and depression may sometimes be impossible to disentangle.²¹

Whatever the relationship between dizziness and anxiety, the treatment solution requires a multidisciplinary approach.

ASSESSMENT

Firstly, a thorough balance and vertigo assessment is required although what really matters are symptoms—(dys)function and (dis)abilities per se—rather than just making an aetiological diagnosis. Many patients with vestibular pathology develop secondary problems—for example, muscular pain from increased muscle tension, particularly in the neck, stress, fatigue and even chronic anxiety. These secondary problems can affect their ability to participate in a rehabilitation programme. Inactivity, whether from bed rest, fear, anxiety or other factors, also delays and impairs complete compensation.



Functional assessment is partly incorporated in the conventional neurological examination, such as the Romberg test, gait assessment, including tandem or heel to toe gait. In addition, observing the patient through sequential actions which can be rated or timed may be useful—for example, the 'Get up and Go' test which is a quick screening tool for detecting balance problems in the elderly²² or the Dynamic Gait Index²³ that examines how the gait is able to adapt to various task demands. These examinations allow a therapist to determine performance levels of functionally relevant tasks, have predictive value (eg, for falls risk) and are also useful for evaluating the effectiveness of therapy.

Systems assessment partly implies detecting any additional sensory–motor or musculoskeletal impairments. Somatosensory, visual and motor function can be assessed with a conventional neurological examination. The type and effectiveness of postural reactions can be examined with gentle or vigorous pushes/pulls to the trunk to elicit ankle, hip or stepping motor postural strategies.²⁴

Symptom assessment involves identifying the primary vestibular symptom and its associated autonomic and psychological correlates. The latter may require additional reassurance or treatment if patients develop anxiety or hyperventilation.

Dizziness triggers (eg, visual stimuli such as large field stimuli (a moving train) or self-motions (travel sickness)). This is critical in guiding therapy since the principle is 'we'll work on whatever turns your dizziness on' (ie, desensitisation treatment), and hence the exercises for the patient will largely

Figure 2

Top: Horizontal eye movement recordings a few days after complete unilateral vestibular loss (labyrinthectomy). Note the prominent nystagmus (alternating slow and fast eye movements) present almost exclusively in the dark, thus illustrating the initial role played by visual input in vestibular compensation. Bottom: A month later the nystagmus is hardly detectable in the dark, indicating central non-visually mediated compensation.

Anxiety and/or depression are associated with long term symptoms and disability

TABLE 1 Relevant questions and investigations in the patient with chronic disequilibrium (slightly modified from Bronstein and Lempert³¹)

Question	Possible diagnosis	Procedure
Oscillopsia?	Downbeat nystagmus syndrome Bilateral loss of vestibular function	Brain MRI Vestibular tests (bedside+laboratory)
Neck or arm pain? Sphincter dysfunction? Long tract signs? Memory loss? Incontinence?	Cervical cord compression/canal stenosis	MRI spine
Slowness, tremor? Motor incoordination? Speech disorder?	Hydrocephalus, or white matter 'small vessel' disease Parkinsonism Cerebellar ataxia	MRI/CT head Neurological examination DAT scan Neurological examination+brain MRI, paraneoplastic and genetic tests
Vascular risk factors? Strokes?	White matter 'small vessel' disease (leucoaraiosis)	Brain MRI/CT Cardiovascular assessment
Distal numbness?	Peripheral neuropathy	Neurological examination+clinical neurophysiology

BOX 2 Common causes of bilateral vestibular failure²⁵

- Idiopathic (either recurrent vertigo or slowly progressive presentations)
- Gentamycin ototoxicity
- Post-meningitis
- Neurological: cranial/peripheral neuropathies, cerebellar degeneration

be based on the findings here (see 'Management of the chronic dizzy patient' below).

THE PATIENT WITH PROGRESSIVE DISEQUILIBRIUM

It is not always easy to separate patients with chronic dizziness following episodes of vestibular vertigo from those with true gait unsteadiness on the basis of history alone. It is important at the outset to sort out if the problem lies in the head or the legs, or both. The patient with subjective chronic dizziness may acknowledge that the abnormal sensation is 'in the head'. They may say they *feel* as if they were drunk but, in contrast with true drunkenness or gait unsteadiness, friends or colleagues will not notice anything wrong with their balance. In contrast, the patient who describes disequilibrium due to gait unsteadiness will usually volunteer that loss of balance is noticed by themselves and observers alike.

Falling is a key objective measure in disequilibrium and falls frequency (or the absolute number of falls) should be recorded. In

addition, falls can help to differentiate patients with disequilibrium (who fall) from those with chronic dizziness (who rarely fall).

The diagnosis of the patient with disequilibrium is heavily guided by the collateral history, in particular any symptoms associated with the underlying disease responsible for the gait unsteadiness. Table 1 provides a few questions useful in guiding the examination and laboratory investigations required to reach a diagnosis. As in any other area of neurology, an MRI of the brain is not enough, and it is definitely no substitute for a neurological history and examination.

BILATERAL VESTIBULAR FAILURE

Most neurologists will usually consider the diagnosis of bilateral vestibular failure when patients report oscillopsia during walking and balance problems in the dark after a course of gentamycin (not deaf) or meningitis (usually deaf). However, they often miss the idiopathic cases (which are at least as common) where the only history is of slowly progressive balance difficulty (sometimes very mild) and oscillopsia during walking, running or riding a vehicle.^{25 26} In some cases there are episodes of vertigo or spontaneous paroxysmal oscillopsia gradually leading into this syndrome. The common causes of bilateral vestibular failure are shown in box 2.

Bilateral vestibular failure can be diagnosed in the clinic with simple clinical tests (figure 3), the most popular being the head thrust or head impulse test (figure 4). For further explanation, see our previous article in *Practical Neurology*.²⁷

THE PATIENT WITH NEITHER VERTIGO NOR DISEQUILIBRIUM

Sometimes patients refer to a sense of vague and chronic dizziness but without any history of 'true' vertigo or any disequilibrium. Hopefully direct questions will guide one to specific organs or systems at fault but this line of enquiry may be negative. A full clinical examination is warranted, including checking for orthostatic hypotension, particularly in the elderly taking drugs for high blood pressure. We suggest having a low threshold for lying and standing blood pressure measurements, even when the history is not typical. Good predictors for a cardiovascular diagnosis in this age group are syncope, dizziness described as light headedness, the need

to sit or lie down during symptoms, pallor with symptoms, symptom precipitation by prolonged standing and coexisting vascular disease.²⁸ But in the elderly, the history may be unreliable due to age related cognitive decline which affects not just recall of any discrete event but sometimes loss of the relevant sensory percept—for example, some older patients do not perceive dizziness during caloric irrigation despite a vigorous nystagmus response. Hence common vestibular diagnoses can be found if specifically looked for in the elderly who complain of vague disequilibrium, in particular one should always check for BPPV.

In general, patients with vague imbalance pose a diagnostic challenge and often numerous investigations are requested—blood tests to rule out general medical conditions such as anaemia, hypothyroidism or other endocrine conditions, diabetes or hypoglycaemia, brain scans and vestibular function tests. With a non-specific history with no pointers to a known disease such as Ménière's and negative investigations, many patients are diagnosed with psychogenic dizziness—rightly or wrongly. Observe, during history taking, if the patient appears to hyperventilate and enquire about frank hyperventilation and anxiety episodes, as well as features which may indicate hyperventilation such as perioral or distal paraesthesia. In our opinion, the active hyperventilation test is not reliable because hyperventilation induces dizziness and unsteadiness in everybody.²⁹ Only when the patient recognises his or her own typical symptoms during voluntary hyperventilation is the test useful. Blood gases and the opinion of a chest physician may be justified in some cases.³⁰

MANAGEMENT OF THE CHRONIC DIZZY PATIENT

There are four equally important components to the management of any patient with dizziness or vertigo, whether acute, recurrent or chronic:

- the treatment of the specific vestibular condition if there is one (eg, BPPV, migraine, etc)
- short term non-specific pharmacological treatment of vertigo and associated nausea
- physical rehabilitation
- the provision of information, counselling and reassurance.

Doll's head and Head thrust



Dynamic funduscopy



VOR: clinical assessment

Dynamic visual acuity

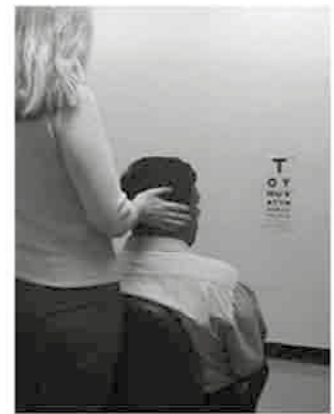


Figure 3

Bedside assessment of the vestibulo-ocular reflex (VOR). All tests rely on the fact that the function of the VOR is to maintain steady gaze (and hence vision) during head movements. During the doll's head-eyes manoeuvre, the patient fixates the examiner's nose while the examiner rotates the head (instruct patient to relax the neck). In patients with bilateral absence of the VOR, even slow head oscillations (1 Hz) render them unable to track the examiner's nose smoothly and small catch up saccades are observed. For the head thrust (or head impulse) test, the head movements imposed by the examiner are discrete, very brisk (ie, high acceleration) and of small amplitude. If the patient has lost the VOR, he or she will need 1–2 catch up saccades at the end of the head movement to be able to re-fixate the examiner's nose (see figure 4). During dynamic funduscopy, the clinician identifies the optic disc and instructs the patient to maintain fixation on a target across the room. Then the head is rotated from side to side. If the VOR is abnormal, again small saccades can be seen as jerky jumps of the disc (make sure not to obstruct the patient's line of sight).⁴⁹ During dynamic visual acuity testing, the patient's acuity is determined binocularly with the head stationary. Then the patient's head is actively oscillated from side to side (and/or up and down) at 1–2 Hz and visual acuity determined again during the head oscillation. Some normal people may lose 1 line of visual acuity (eg, 6/6 to 6/9) but patients with bilateral vestibular failure usually lose 3 or more lines. The head movement has to be actively imposed by the examiner because the patients develop an astute compensatory tactic of briefly stopping the head movement to take a snapshot of the visual chart.

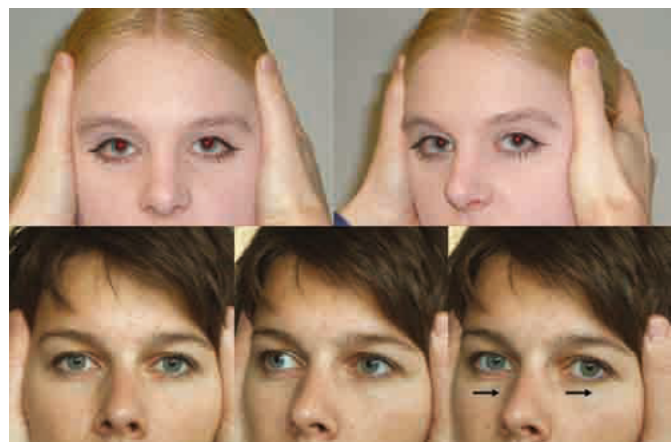


Figure 4

A normal (top) and abnormal (bottom) head thrust test.⁵⁰ (For a video demonstration, see www.imperial.ac.uk/medicine/balance/research.) In the bottom picture, the right horizontal semicircular canal system is abnormal (hence the catch up saccades to the left when the head turns towards the abnormal labyrinth). In patients with bilateral vestibular dysfunction, the abnormal catch up saccades may be seen with head turns in any direction.

Long term vestibular suppressants and tranquilisers are counterproductive

However, not all patients require action in all four domains. For instance, patients with BPPV usually require repositioning treatment and nothing else. Patients with migrainous vertigo, if they do not have interictal or chronic symptoms, may just require antimigraineous drugs but no rehabilitation. In contrast, patients with chronic dizziness typically require counselling and rehabilitation, but no drugs.

Disease specific treatment

If an active underlying vestibular disorder is identified, such as BPPV or Ménière's disease, this needs to be treated because, with each vertigo attack, the chronic symptoms tend to increase.²⁷⁻³¹ It is particularly important to treat migraine since migraine can both cause vertigo and be triggered by it.³²⁻³³

Non-disease specific pharmacological treatment

Vertigo or nausea can be reduced with medications but only for the acute attack or the recurrent episode. Long term vestibular suppressants and tranquilisers are inimical to the process of vestibular compensation. These drugs should only be used for truly acute vertigo and stopped as soon as vertigo begins to recede.

The doctor should briefly describe the process of vestibular compensation to the patient and explain that, for compensation to occur, the brain must feel some vertigo. This sensation will function as a warning signal and so compensation processes will be set in motion. Essentially, 'no vertigo, no warning signal and hence no compensation'. Despite this explanation it can be difficult to wean patients off medication they may have taken for a long time and one may have to compromise and let rehabilitation begin before complete medication withdrawal.

General support

Reassurance, information and counselling are all important. Patients with long term dizziness have often wandered from clinic to clinic, from specialist to specialist, sometimes for months or years. On the basis of normal brain scans some doctor is likely to have said 'there's nothing wrong with you', or 'there's nothing that medical science can do for you' or, worse, 'it's all in your mind'. This is not only the wrong approach but it is usually not true. Patients may

have suffered a genuine vestibular insult in the past which may not show up in conventional vestibular testing but of course failures in the vestibular compensation process and/or added psychological problems complicate the situation (box 1). Because rehabilitation works even in patients with many years of chronic dizzy symptoms,²⁴ you want your patient to cooperate in this process. So you need to explain the principles of vestibular compensation and rehabilitation. There are many useful web pages and leaflets which are helpful (eg, the British Brain and Spine Foundation <http://www.bbsf.org.uk> or the Vestibular Disorders Association <http://www.vestibular.org>). Motivated patients, actively engaged in the rehabilitation process, fare better than patients who develop an external locus of control, feeling they have no power over their clinical outcome.¹⁹

You may also need to mention that anxiety and depression are very common in patients with dizziness but that this does not mean the symptoms are imaginary or, worse, the result of malingering. Most patients have psychological complications. Separating 'organic from psychogenic' or 'primary from secondary' is deeply engrained in our medical training but nowhere is it more difficult to do this than in the patient with chronic 'dizziness'. The effort to distinguish organic from psychogenic may not even always be worthwhile; indeed, many patients are willing to undertake cognitive behavioural or other psychotherapies if they see this as part of a global 'body and soul' effort. Some patients may need antidepressants, particularly on initiating the rehabilitation process. There is no evidence that antidepressants interfere with vestibular compensation or rehabilitation, and some studies suggest a positive effect.³⁴

Rehabilitation

The complexity of the rehabilitation programme depends on how much, if any, rehabilitation and advice your patient has already had, and how much access you have to vestibular rehabilitation services and how good these services are. For the patient who has been ill advised to stay in bed and to take tablets when dizzy, simple factual explanation, encouragement to begin activity and progressive reduction in medication may be enough. The other end of the spectrum is the patient who has already

completed a course of conventional vestibular rehabilitation but has developed visual vertigo (see below). This patient may need specialised vestibular rehabilitation, including optic flow techniques.²⁴ Most chronic dizzy patients are likely to be in between these two extremes.

A key aspect is understanding that the control of balance emerges from an interaction between many sensorimotor systems. Thus the purpose of rehabilitation is to maximise the natural ability of the CNS to compensate for lesions in the vestibular system. The neural basis for vestibular compensation is distributed throughout the nervous system such that lesions in the cerebellum, cortex, spinal cord, brainstem or sensory systems can prevent or reduce the capacity for compensation. Vestibular compensation is a plastic process that allows the CNS to restore functional symmetry after a unilateral peripheral vestibular lesion (figure 2). Patients with both unilateral and bilateral vestibular loss also compensate by a process of sensory substitution by which they learn to use non-vestibular information for balance—namely, visual and proprioceptive inputs. Although this is obviously a useful compensatory process it can also create some new problems—for example, patients unduly dependent on visual input for balance and spatial orientation may become dizzy in the presence of visual motion stimulation ('visual vertigo' as discussed below).

We will now outline how to organise a rehabilitation programme because many doctors may not have access to an audiologist or physiotherapist specifically trained in vestibular rehabilitation. An important comorbidity to consider prior to embarking on vestibular rehabilitation is migraine which is often aggravated by vestibular exercises. We thus advise that any active migraine should be effectively treated before starting vestibular rehabilitation.^{32,33}

REHABILITATION TREATMENT OF BALANCE DISORDERS

Vestibular ('Cawthorne-Cooksey') exercises consist of eye, head and postural exercises of increasing complexity (box 3).³⁵ They are intended to include those eye, head or body positions and movements which provoke vertigo. A list of exercises can be given to the patient with the instruction to go down the list identifying which ones are symptom

BOX 3 Vestibular rehabilitation exercises*

- Head exercises (with eyes open and closed)
 - Bend head backwards and forwards
 - Turn head from side to side
 - Tilt head from one shoulder to the other
- Fixation exercises
 - Move eyes up and down, side to side
 - Perform head exercises while fixating stationary target
 - Perform head exercises while fixating moving target
- Positioning exercises (with eyes open and closed)
 - While seated, bend down to touch the floor
 - Bend down with head twisted first to one side and then the other
 - Lying down, roll from one side to the other
 - Sit up from lying on the back and on each side
 - Repeat with head turned to each side
- Postural exercises (with eyes open and eyes closed under supervision)
 - Practice static stance with feet as close together as possible
 - Practice standing on one leg, and heel to toe
 - Repeat head fixation exercises while standing and then walking
 - Practice walking in circles, pivot turns, up slopes, stairs, around obstacles
 - Standing and walking in environments with altered surface and/or visual conditions with and without head and fixation exercises
 - Exercises including alternate touching the toes, trunk bends and twists, etc

Note: The exercise programme for a given patient will depend on their symptoms and triggers for their symptoms.

*Exercises and treatment repositioning procedures can be seen in a DVD (Bronstein and Lempert²⁷).

provoking; these the patients should concentrate on.

The exercises should be performed for 10–15 min twice a day. 'Pacing' is crucial because unless the exercises are performed slowly at first they will induce unacceptable vertigo and nausea. The patient should gradually increase the pace and difficulty of the exercises as the provoked dizziness progressively abates. It is important to foster positive but realistic expectations. Patients must be told that their symptoms will at first worsen and that improvement may be uneven. Although generic exercise programmes, either provided as leaflets or group physiotherapy sessions, achieve good results, customised therapy results are superior.³⁶ In addition, the rehabilitation professional will work on all other limitations and impairments noted during the balance therapy assessment. This will include re-training of appropriate postures such as ankle, hip and stepping strategies. Similarly, he or she will attempt to redress any

The purpose of rehabilitation is to maximise the natural ability of the CNS to compensate for lesions in the vestibular system

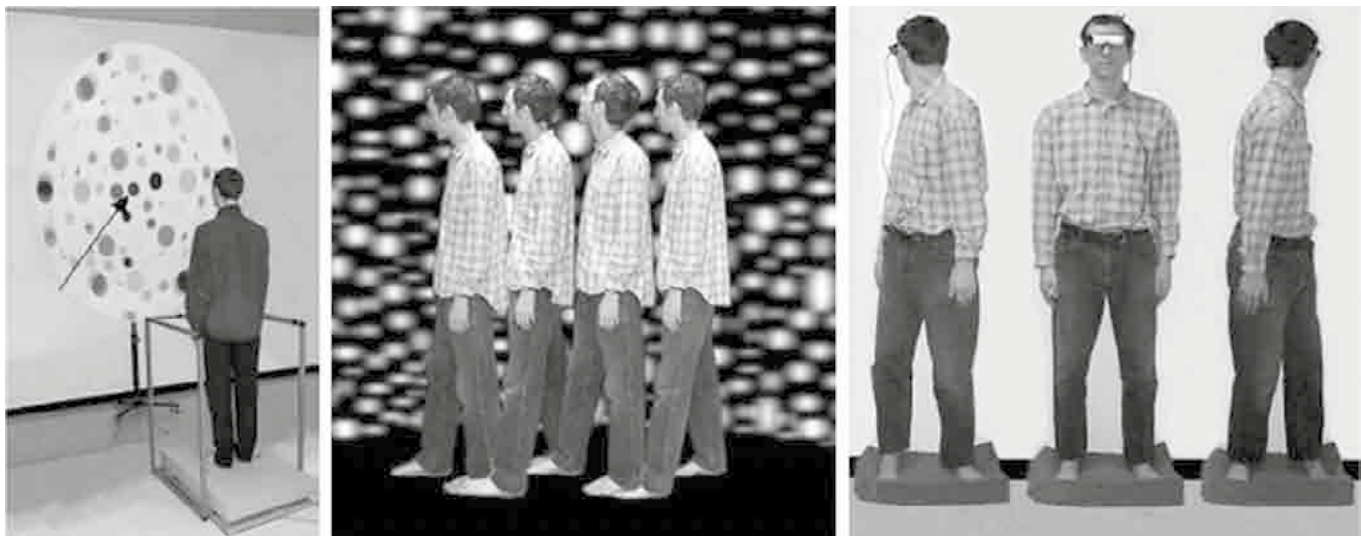


Figure 5

Examples of the type of visual stimulation employed in the desensitisation of patients with chronic dizziness and visual vertigo. Left: A rotating disc. Centre: Gait exercises during planetarium projection. Right: Optokinetic stimuli delivered by the Eyetrek or virtual reality systems; the patient stands on foam to decrease the accuracy of the lower limb proprioceptive input. Modified from Pavlou *et al.*²⁴




Figure 6

Different head and eye movements to be included as part of a vestibular rehabilitation programme. During 'gaze stability' exercises, the patient is stimulating the vestibulo-ocular reflex (VOR)—that is, keeping the eyes steady on a fixated object as the head moves progressively faster. During 'gaze transfer', the patient practises the normal head and eye synergy for transferring gaze from one object to another. During 'VOR suppression', the patient tries to fixate or read from an object that she carries around (like reading a newspaper on a bus).

surface or visual dependence (figure 5 and bottom of figure 6). Decreasing a patient's hypersensitivity to visual motion cues can be done by balancing during exposure to optokinetic stimuli, virtual reality sets or simply watching complex computer games on a big screen.

All exercises or situations that are symptom provoking have to be made progressively more complex as the patient is desensitised. For instance, if a patient is dizzy when turning the head from side to side, this exercise will be initially practised just while seated, then standing, walking, walking on a mattress or standing on one foot at a time, or with eyes closed. The principle is adding complexity to cover as many circumstances as possible so that when the patient has to move their head in an everyday life situation all possibilities have been practised beforehand.

Not all patients need so much work up. In many cooperative patients an explanation of the principles of vestibular compensation and how this is achieved through graded activity is enough. The next step up would be a list of the exercises in box 3, with an explanation to identify the symptom provoking ones, a twice a day activity schedule and an indication to progressively intensify the pace. However, better to encourage an audiologist or physiotherapist in your hospital to become interested in balance rehabilitation.

LAST BUT NOT LEAST, SOME SPECIFIC SYNDROMES OF CHRONIC DIZZINESS TO BE AWARE OF

Visual vertigo

These are the patients with chronic dizziness whose symptoms are worse in certain 'visually busy' surroundings. The syndrome has been given different names such as visual vertigo,^{37, 38} visuo-vestibular mismatch³⁹ and space and motion discomfort.⁴⁰ Frequent triggers are walking between shelves in supermarket aisles, and viewing movement of large visual objects such as clouds, windswept trees, rivers flowing, disco lights, crowds, traffic, curtains or films with car chase scenes. Repetitive visual patterns like the stacks of cans on supermarket shelves, ironing striped shirts or walking past a repetitive patterned fence seem to be relevant. Some patients also mention that moving their eyes, reading and flickering or fluorescent light can make them feel dizzy.

Some patients with vestibular lesions become overly sensitive to visual stimuli. However, an increased sensitivity to visual signals is a normal response to vestibular disease ('sensory substitution') but this process may be exaggerated in patients with visual vertigo.^{39, 41-43} Why some patients develop visual dependence and visual vertigo is not known but migraine appears to be a predisposing factor.⁴⁴ We do know, however, that visual vertigo can be improved by rehabilitation which includes customised vestibular therapy with additional visual motion desensitisation²⁴ (figure 3).

Motorist disorientation syndrome

Driving, particularly on motorways, can be uncomfortable for patients with vestibular disorders and chronic dizziness. Occasionally, they report a sensation that their car is tilting or veering to one side which is so compelling that they consult their mechanic or change their car before seeing their doctor. This syndrome⁴⁵ also seems to be, at least partly, visually determined because patients describe problems in visually deprived areas (top of a hill) and visually challenging conditions (simultaneously overtaking and being overtaken by a car). Indeed the coexistence of visual vertigo and motorist disorientation syndrome in the same patient is not rare.

Going round a bend, as when driving in a roundabout, can also disorient patients but here there may be a predominantly vestibular mediated component. It must be kept in mind that driving through a curve is different to just turning round while walking. The radius of curvature is large while driving so the conditions are equivalent to being centrifuged and that is why you feel pushed sideways against the car door. In this case the unusual stimulation (sideways linear acceleration) acting on a damaged otolith system may be responsible for the symptoms. Psychological components, usually in the form of panic and avoidance behaviour, can contribute. In fact, in patients with no vestibular history or findings, a psychological disorder may be the only mechanism responsible.⁴⁶ In these patients, however, there is usually more 'panic' and less 'veering and tilting' of the car.

In those with motorist disorientation syndrome, a previous history of vestibular disease and no panic component, treatment is based on vestibular rehabilitation with the addition of visuo-vestibular conflict and optic flow stimuli. In patients with mostly panic symptoms but no vestibular disease, the treatment is predominantly psychiatric, often combining medication with cognitive behavioural therapy.⁴⁷ Many patients fall between these two extremes and are accordingly managed with a combination of treatments.

Psychological presentations, phobic postural vertigo, panic attacks

The term 'phobic postural vertigo' describes patients with transient sensations of unsteadiness in whom postural balance is entirely normal on extensive clinical examination.⁴⁸ Patients may deny psychological disturbance but excessive anxiety or an obsessive-compulsive personality may be apparent. Panic attacks, in which patients describe autonomic symptoms, catastrophic thoughts and avoidance behaviour can also turn up in dizzy patient clinics mimicking vestibular initiated chronic dizziness.

A complicating factor is that in approximately 30% of patients with these 'psychogenic' syndromes a vestibular onset such as BPPV, migraine or vestibular neuritis can be elicited.⁴⁸ Another complication is that some symptoms of the visual vertigo and motorist disorientation

All exercises or situations that are symptom provoking have to be made progressively more complex as the patient is desensitised

TABLE 2 Summary of our approach to the patient with chronic vestibular symptoms (slightly modified from Bronstein and Lempert³¹)

Approach	Specific goals—try to establish:
Attempt retrospective diagnosis	Did it all start as BPPV, vestibular neuritis, recurrent vertigo (eg, migraine, Ménière's disease), brainstem stroke? Are the original symptoms still present? Or are we only dealing with chronic dizzy symptoms?
Other potentially important problems	Is vestibular compensation impeded due to additional problems? Fluctuating vestibular disorder, recurrent vertigo Visual problems such as squint, cataract operation Proprioceptive deficit such as peripheral neuropathy (diabetes/alcohol) Neurological problems such as 'small vessel' white matter disease Orthopaedic problems and lack of mobility Loss of confidence, fear of falling, psychological disorders Age: all of the above possible but try to identify which one(s)
Treatment is multidisciplinary	Treat any episodic vertigo specifically: BPPV: repositioning manoeuvres Vestibular migraine: migraine prophylaxis Ménière's disease: low salt diet, diuretics, betahistine Rehabilitation (and simple counselling): all patients Treat underlying complicating factors: eg, orthopaedic, depression, diabetes, migraine Do <i>not</i> prescribe vestibular suppressants or tranquilisers, stop/reduce them if possible
Make sure the 'chronic dizziness' is not a gait disorder	'Is your problem a head problem or a leg problem?' Ask about falls Observe: gait (including heel to toe), postural reactions and Romberg's sign Eye movement and neurological examination: Bilateral vestibular failure: oscillopsia, unsteady in the dark, abnormal doll's head/head thrust test Cerebellum: abnormal eye movements, gait/limb ataxia Parkinsonism: rest tremor, increased tone, akinesia Spasticity: increased reflexes, Babinski's sign Peripheral neuropathy: distal weakness (cannot walk on heels or toes) and sensory loss Frontal disorder/hydrocephalus: gait 'ignition' failure, gait apraxia, shuffling
BPPV, benign paroxysmal positional vertigo.	

syndromes overlap with phobic postural vertigo and panic. It may well be that some of these presentations are just normal modes of reaction that humans have to different disorders. A

vestibular disorder or a psychological problem may lead to a similar final clinical result.

In terms of treatment, each patient needs to be considered on his or her own merits. Two examples at opposite ends of a spectrum would be the patient who has no pre-existing psychiatric history but just vestibular neuritis leading to chronic dizziness with visual vertigo and another patient with general anxiety and panic attacks in the supermarket in whom, despite direct questioning and specialised balance examination, no vestibular features are detected. There is little doubt that the former patient should receive vestibular treatment, usually rehabilitation including visual motion desensitisation, and that the latter should be in the hands of a psychiatrist or cognitive behavioural therapist. The many patients in between these two examples often require combined treatment. Ideally, vestibular therapists, whatever their background (audiologists or physiotherapists) should have counselling skills so they can deal with the very common anxiety, depressive or phobic components that so many patients have (table 2).

ACKNOWLEDGEMENTS

This article was reviewed by Richard Metcalfe, Glasgow.

Funding AMB is supported by a research grant from the Medical Research Council of the UK. BMS is an Academy of Medical Sciences and the Health Foundation Clinician Scientist.

Provenance and peer review Commissioned; externally peer reviewed

Competing interests None.

REFERENCES

1. **Matthews B.** *Practical neurology*, 3rd edn. Oxford: Blackwell, 1975:76.
2. **Neuhauser HK, Radtke A, von Brevern M, et al.** Burden of dizziness and vertigo in the community. *Arch Intern Med* 2008;**168**:2118–24.
3. **Odman M, Maire R.** Chronic subjective dizziness. *Acta Otolaryngol* 2008;**128**:1085–8.
4. **Lempert T, Neuhauser H.** Migrainous vertigo. *Neurol Clin* 2005;**23**:715–30, vi.
5. **Sajjadi H, Paparella MM.** Ménière's disease. *Lancet* 2008;**372**:406–14.
6. **Darlington CL, Dutia MB, Smith PF.** The contribution of the intrinsic excitability of vestibular nucleus neurons to recovery from vestibular damage. *Eur J Neurosci* 2002;**15**:1719–27.
7. **Curthoys IS.** Vestibular compensation and substitution. *Curr Opin Neurol* 2000;**13**:27–30.
8. **Barmack NH.** Central vestibular system: vestibular nuclei and posterior cerebellum. *Brain Res Bull* 2003;**60**:511–41.
9. **Fetter M, Zee DS, Proctor LR.** Effect of lack of vision and of occipital lobectomy upon recovery

from unilateral labyrinthectomy in rhesus monkey. *J Neurophysiol* 1988;**59**:394–407.

10. **Seemungal BM**, Gresty MA, Bronstein AM. The endocrine system, vertigo and balance. *Curr Opin Neurol* 2001;**14**:27–34.
11. **Yamamoto T**, Yamanaka T, Matsunaga T. The effect of stress application on vestibular compensation. *Acta Otolaryngol* 2000;**120**:504–7.
12. **Cousins S**, Cutfield N, Seemungal BM, et al. Vestibular perception after acute vestibular neuritis. *Eur J Neurol* 2009 abstracts EFNS (in press).
13. **Kanayama R**, Bronstein AM, Gresty MA, et al. Perceptual studies in patients with vestibular neurectomy. *Acta Otolaryngol Suppl* 1995;**520**:408–11.
14. **Palla A**, Straumann D, Bronstein AM. Vestibular neuritis: vertigo and the high-acceleration vestibulo-ocular reflex. *J Neurol* 2008;**255**:1479–82.
15. **Penfield W**. Vestibular sensation and the cerebral cortex. *Ann Otol Rhinol Laryngol* 1957;**66**:691–8.
16. **Kahane P**, Hoffmann D, Minotti L, et al. Reappraisal of the human vestibular cortex by cortical electrical stimulation study. *Ann Neurol* 2003;**54**:615–24.
17. **Seemungal BM**, Rizzo V, Gresty MA, et al. Posterior parietal rTMS disrupts human Path Integration during a vestibular navigation task. *Neurosci Lett* 2008;**437**:88–92.
18. **Godemann F**, Koffroth C, Neu P, et al. Why does vertigo become chronic after neuropathia vestibularis? *Psychosom Med* 2004;**66**:783–7.
19. **de Ridder D**, Geenen R, Kuijer R, et al. Psychological adjustment to chronic disease. *Lancet* 2008;**372**:246–55.
20. **Eckhardt-Henn A**, Best C, Bense S, et al. Psychiatric comorbidity in different organic vertigo syndromes. *J Neurol* 2008;**255**:420–8.
21. **Furman JM**, Balaban CD, Jacob RG, et al. Migraine–anxiety related dizziness (MARD): a new disorder? *J Neurol Neurosurg Psychiatry* 2005;**76**:1–8.
22. **Podsiadlo D**, Richardson S. The timed "Up & Go": a test of basic functional mobility for frail elderly persons. *J Am Geriatr Soc* 1991;**39**:142–8.
23. **Whitney S**, Wrisley D, Furman J. Concurrent validity of the Berg Balance Scale and the Dynamic Gait Index in people with vestibular dysfunction. *Physiother Res Int* 2003;**8**:178–86.
24. **Pavlou M**, Lingeswaran A, Davies RA, et al. Simulator based rehabilitation in refractory dizziness. *J Neurol* 2004;**251**:983–95.
25. **Rinne T**, Bronstein AM, Rudge P, et al. Bilateral loss of vestibular function: clinical findings in 53 patients. *J Neurol* 1998;**245**:314–21.
26. **Wagner JN**, Glaser M, Brandt T, et al. Downbeat nystagmus: aetiology and comorbidity in 117 patients. *J Neurol Neurosurg Psychiatry* 2008;**79**:672–7.
27. **Seemungal BM**, Bronstein AM. A practical approach to acute vertigo. *Pract Neurol* 2008;**8**:211–21.
28. **Lawson J**, Fitzgerald J, Birchall J, et al. Diagnosis of geriatric patients with severe dizziness. *J Am Geriatr Soc* 1999;**47**:12–17.
29. **Sakellari V**, Bronstein AM, Corna S, et al. The effects of hyperventilation on postural control mechanisms. *Brain* 1997;**120**:1659–73.
30. **Naschitz JE**, Mussafia-Priselac R, Kovalev Y, et al. Patterns of hypocalcemia on tilt in patients with fibromyalgia, chronic fatigue syndrome, nonspecific dizziness, and neurally mediated syncope. *Am J Med Sci* 2006;**331**:295–303.
31. **Bronstein AM**, Lempert T. *Dizziness—a practical approach to diagnosis and management*. Cambridge: Cambridge University Press, 2007.
32. **Seemungal B**, Rudge P, Davies R, et al. Three patients with migraine following caloric-induced vestibular stimulation. *J Neurol* 2006;**253**:1000–1.
33. **Murdin L**, Davies RA, Bronstein AM. Vertigo as a migraine trigger. *Neurology* 2009;**73**:638–42.
34. **Staab JP**. Chronic dizziness: the interface between psychiatry and neuro-otology. *Curr Opin Neurol* 2006;**19**:41–8.
35. **Pavlou A**, Shumway-Cook A, Horak F, et al. Rehabilitation of balance disorders in the patient with vestibular pathology. In: Bronstein AM, Brandt T, Woollacott MH et al, eds. *Clinical disorders of balance, posture and gait*. London: Arnold Publishers, 2004.
36. **Badke MB**, Shea TA, Miedaner JA, et al. Outcomes after rehabilitation for adults with balance dysfunction. *Arch Phys Med Rehabil* 2004;**85**:227–33.
37. **Bronstein AM**. Visual vertigo syndrome: clinical and posturography findings. *J Neurol Neurosurg Psychiatry* 1995;**59**:472–6.
38. **Guerraz M**, Yardley L, Bertholon P, et al. Visual vertigo: symptom assessment, spatial orientation and postural control. *Brain* 2001;**124**:1646–56.
39. **Longridge NS**, Mallinson AI, Denton A. Visual vestibular mismatch in patients treated with intratympanic gentamicin for Ménière's disease. *J Otolaryngol* 2002;**31**:5–8.
40. **Furman JM**, Jacob RG. A clinical taxonomy of dizziness and anxiety in the otoneurological setting. *J Anxiety Disord* 2001;**15**:9–26.
41. **Pavlou M**, Davies RA, Bronstein AM. The assessment of increased sensitivity to visual stimuli in patients with chronic dizziness. *J Vestib Res* 2006;**16**:223–31.
42. **Bronstein AM**. Visually induced paroxysmal nausea and vomiting as presenting manifestations of multiple sclerosis. *J Neurol Neurosurg Psychiatry* 1996;**60**:703.
43. **Khan OA**, Sandoz GM, Olek MJ, et al. Visually induced paroxysmal nausea and vomiting as presenting manifestations of multiple sclerosis. *J Neurol Neurosurg Psychiatry* 1995;**59**:342–3.
44. **Drummond PD**. Triggers of motion sickness in migraine sufferers. *Headache* 2005;**45**:653–6.
45. **Page NG**, Gresty MA. Motorist's vestibular disorientation syndrome. *J Neurol Neurosurg Psychiatry* 1985;**48**:729–35.
46. **Taylor J**, Deane F, Podd J. Driving-related fear: a review. *Clin Psychol Rev* 2002;**22**:631–45.
47. **Townend M**, Grant A. Integrating science, practice and reflexivity—cognitive therapy with driving phobia. *J Psychiatr Ment Health Nurs* 2006;**13**:554–61.
48. **Brandt T**. Phobic postural vertigo. *Neurology* 1996;**46**:1515–19.
49. **Zee DS**. Ophthalmoscopy in examination of patients with vestibular disorders. *Ann Neurol* 1978;**3**:373–4.
50. **Halmagyi GM**, Curthoys IS. A clinical sign of canal paresis. *Arch Neurol* 1988;**45**:737–9.

PRACTICE POINTS

- Try to differentiate between vertigo, disequilibrium and non-specific dizziness.
- Consider somatic causes of chronic dizziness, including poorly compensated unilateral vestibular loss, bilateral vestibular failure, end-stage Ménière's disease, undiagnosed BPPV, chronic migrainous vertigo, sensory and motor dysfunction of the legs, visual failure, orthopaedic problems and drug toxicity.
- Explore psychological aspects, particularly anxiety, which may cause or complicate chronic dizziness.
- For treatment use disease specific approaches and rehabilitation targeted at functional impairments.

REVIEW

Pract Neurol 2008; 8: 211–221

A practical approach to acute vertigo

Barry M Seemungal, Adolfo M Bronstein

Patients complaining of symptoms of acute vertigo present a diagnostic challenge for the clinician; the main differential diagnoses are acute unilateral peripheral vestibulopathy ("vestibular neuritis"), cerebellar stroke or migraine. The head impulse test is useful in the acute situation because, of these three diagnostic alternatives, it will only be positive in patients with vestibular neuritis. A history of acute vertigo and hearing loss suggests Ménière's disease but the clinician must be wary of anterior inferior cerebellar artery strokes which may cause audiovestibular loss due to peripheral vestibulocochlear ischaemia, although the accompanying brainstem signs should remove diagnostic ambiguity. We also discuss other less common vertigo diagnoses that may be referred to the neurologist from the acute general hospital take. As ever in neurology, a careful history and focussed examination is necessary in the evaluation and management of acute vertigo.

Dizziness is a common acute complaint; one Italian study reported a population-based incidence of 3.6 cases per 100 000 person-years presenting to the emergency department.¹ The exact frequency of specific vertigo diagnoses remains unclear however, partly because emergency and general internal physicians are not very good at neurological diagnosis (one prospective study found that a

neurological review resulted in a "complete change of diagnosis" in 53% of acute admissions with neurological symptoms).²

In practice, making a diagnosis is most problematic when faced with vertigo *without* additional focal neurological symptoms. We will therefore discuss first the clinical approach for patients presenting with acute isolated vertigo, and then second with acute vertigo and deafness.

B M Seemungal

Clinician Scientist and Consultant Neurologist

A M Bronstein

Professor of Neuro-otology and Consultant Neurologist

Neuro-otology Unit, Department of Clinical Neuroscience, Imperial College London, Charing Cross Hospital, London, UK

Correspondence to:

Dr B M Seemungal
Neuro-otology Unit, Department of Clinical Neuroscience, Imperial College London, Charing Cross Hospital, London W6 8RF, UK;
b.seemungal@imperial.ac.uk

Box 1 History taking tips in acute dizziness

- Make sure that both you and the patients are speaking the same language. Do they mean dizziness in the sense that you mean dizziness? Perhaps describe the sensation that you understand to mean dizziness to the patients, and ask if that is the symptom they have. Beware that oscillopsia is sometimes confused with dizziness (although dizziness and oscillopsia may occur together); dizziness can be present in the blind or in the dark, whereas oscillopsia can only occur when the patient can see.
- Avoid labels: obtain a description of the "dizziness" symptoms in the patient's own words.
 - Rotatory: horizontal "merry-go-round" (synonymous with vertigo) or vertical plane "head over heels"
 - Rocking: "like being on the deck of a boat"
 - Linear: horizontal or vertical plane (including falling).
- What exactly is the duration of any attack?
 - Subjective recall of time can be highly inaccurate, particularly at the lower end of the scale (seconds to minutes). Patients with benign positional paroxysmal vertigo (BPPV) may say that their dizziness lasted "just a couple of minutes". Count out aloud and ask patients to say "stop" when the recalled duration of intense spinning dizziness has abated. Time and again patients who describe their dizziness as lasting minutes will say "stop" after a few seconds!
 - Continuous or prolonged symptoms: after an episode of BPPV it is common for patients to feel destabilised for minutes, hours or even an entire day. If the clinician is not careful they may then obtain a history of prolonged dizziness and so be diverted from the correct diagnosis. Any prolonged symptoms will not be violent spinning vertigo but something more non-specific. Hence it cannot be over-emphasised that the clinician must get an accurate description of the patient's prolonged "dizzy" symptoms—"what does it feel like?" (for example, spinning, rocking, etc) to avoid confusing continuous "dizziness" with that of the acute vertiginous attack.

CLINICAL APPROACH TO THE PATIENT WITH ACUTE VERTIGO

In a patient presenting with acute vertigo, the main questions are:

- where is the lesion, central or peripheral?
- does this patient require immediate neuroimaging?

History taking

Patients use the term "dizziness" to describe a variety of subjective experiences and so very careful clarification is needed to avoid diagnostic mistakes (box 1). Rotational dizziness (vertigo) implies disturbance of the semicircular canals or their central pathways, particularly in the acute phase. In the improving, post-acute phase, many patients with vestibular disorders report other forms of dizziness, using words such as "giddiness"

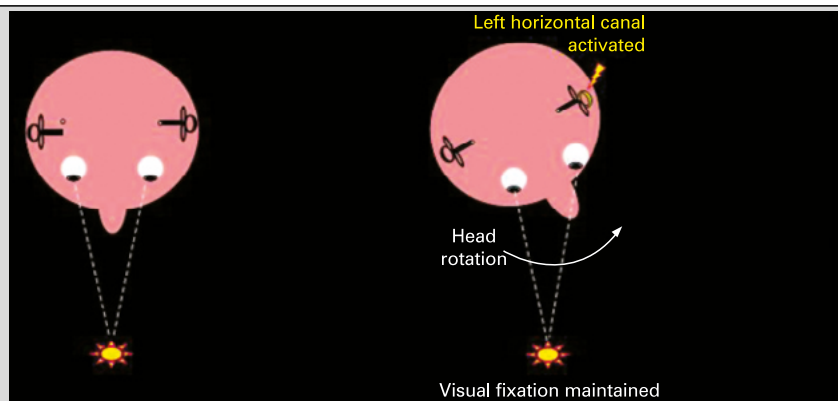
or "light headedness", but beware because patients with general medical conditions (anaemia, hypoglycaemia), haemodynamic (orthostatic hypotension, pre-syncope) or psychological problems also use these very same words. Furthermore, sensory-motor disorders of the lower limbs (parkinsonism, gait ataxia, spinal cord syndromes) come into the differential diagnosis when patients describe their symptoms as imbalance or unsteadiness. It can be useful to ask patients if the problem is "in their legs or in their head" and whether the sensations are as if they are "about to faint" (pre-syncope) as opposed to "being on a merry-go-round" or "on a boat" (vestibular).

Physical examination

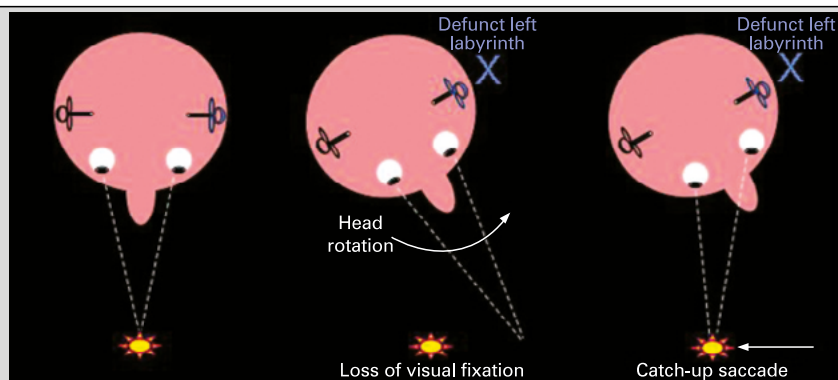
In deciding "is it peripheral or central?", a simple understanding of basic vestibular physiology (figs 1 and 2) is helpful in explaining many of the important clinical findings (table).

- *Unidirectional nystagmus*: in acute peripheral vestibular loss, the nystagmus is unidirectional (that is, the *direction* of the nystagmus is unaffected by changes in the direction of gaze) with the *slow* phase in the direction of the defunct labyrinth (that is, fast phase beating to the contralateral side). The nystagmus will be most visible when looking in the direction of the fast phase, less so in the midline, and least in the opposite direction (that is, the *intensity* but not direction of "vestibular" nystagmus is affected by gaze direction). Note that unidirectional nystagmus confirms that the nystagmus is "vestibular" in origin and while typical for a peripheral lesion, this can also be seen in central vestibular lesions involving the brainstem (where additional signs make localisation relatively easy).
- *Vestibular-ocular reflex (VOR) testing*: the VOR is impaired in peripheral vestibular loss. This is demonstrable when the head (face) is moved in the direction of the damaged labyrinth (or vestibular nerve). The head-impulse (or head-thrust) test is the method of choice in clinically assessing the integrity of the VOR in the acute phase (fig 3). A video demonstrating the head impulse test can be found on the weblink at the end of this article (more

The normal state. Head movement towards a canal (yellow in figure) will cause (i) activation of that canal (ii) reflex movement of the eyes in the opposite direction—that is, away from the canal.



The pathological state and the basis of the head-impulse test. Head movement towards a defunct canal (blue in figure) will result in failure of activation of the VOR and thus the visual target will be lost from fixation during sudden head movements. In the head impulse test, the examiner turns the patient's head with a high acceleration but low amplitude head thrust, in this case to the patient's left. A positive test is observed when the patient makes a catch-up saccade to re-fixate the visual target (usually towards the examiner's nose).



extensive video tutorials on "how to do it" as well as normal and abnormal examples can be found in Bronstein and Lempert).³

- **Suppression of nystagmus:** a key sign of "peripheral" vestibular dysfunction is the suppression of unidirectional vestibular nystagmus when visual fixation is allowed. Conversely, without visual fixation, as in the dark, the nystagmus intensity is increased (that is, faster

slow-phase velocity). The ability to suppress spontaneous nystagmus in the light suggests intact central (mainly cerebellar) mechanisms. Frenzel's glasses, an ophthalmoscope, or even observing the nystagmus beating behind closed eyelids can be used to examine the effect of loss of visual fixation on nystagmus intensity. If using an ophthalmoscope to detect nystagmus, it must be remembered that the observed direction of retinal movement (posterior aspect of the globe) is

Figure 1
Vestibular-ocular reflex (VOR) physiology made simple.

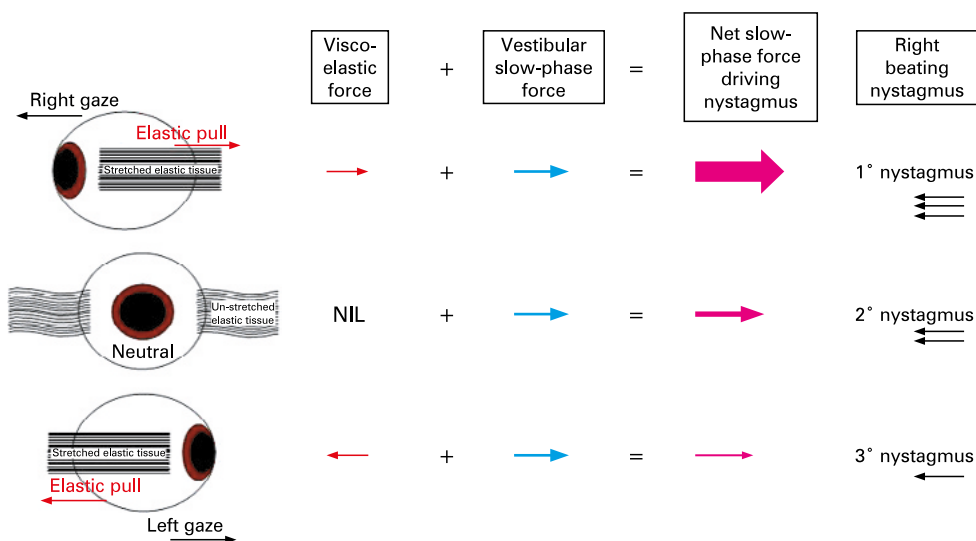


Figure 2
Unidirectional vestibular nystagmus: 1°, 2° and 3° nystagmus. Consider a left beating vestibular lesion where eye tends to drift leftward due to left hypofunction (viz. relative right overactivity). The leftward slow-phase vestibular bias (blue arrow) when added to visco-elastic forces (red arrow) will produce a net slow-phase force (pink arrow) pulling on the eye. In this way we can see clearly why in this case, looking towards the right will elicit the greatest net (leftward) slow-phase force and hence right gaze is the eye position that will most easily generate a right beating nystagmus; viz first-degree (1°) right-beating nystagmus. Nystagmus occurring in the neutral (2° nystagmus) and left gaze (3° nystagmus) are progressively less likely to occur.

TABLE Clinical signs in acute vertigo: peripheral or central?

Sign	Feature	Peripheral	Central
Vestibular ocular reflex	Head impulse test	Impaired	Intact
Spontaneous nystagmus	Nystagmus direction	*Mixed horizontal/torsional	†Pure horizontal ‡Pure vertical
§Spontaneous nystagmus	Suppression of nystagmus with visual fixation	Yes	No
§Smooth pursuit	Is pursuit "smooth" or "broken"?	Pursuit is intact. Can be difficult to assess with vigorous spontaneous nystagmus	Pursuit is broken in ipsilesional direction
Positional nystagmus		Latency Adaptability Fatiguability	No latency No adaptation No fatiguability

*Mixed horizontal/torsional—typical for vestibular neuritis nystagmus but can occur with central lesion.

†Pure horizontal—usually central but could occur with a lesion isolated to a single horizontal canal (or connections).

‡Pure vertical—usually central but could occur with bilateral, simultaneous lesions affecting either both anterior canals or both posterior canals (or their connections).

§Suppression of vestibular nystagmus requires intact smooth pursuit mechanisms.

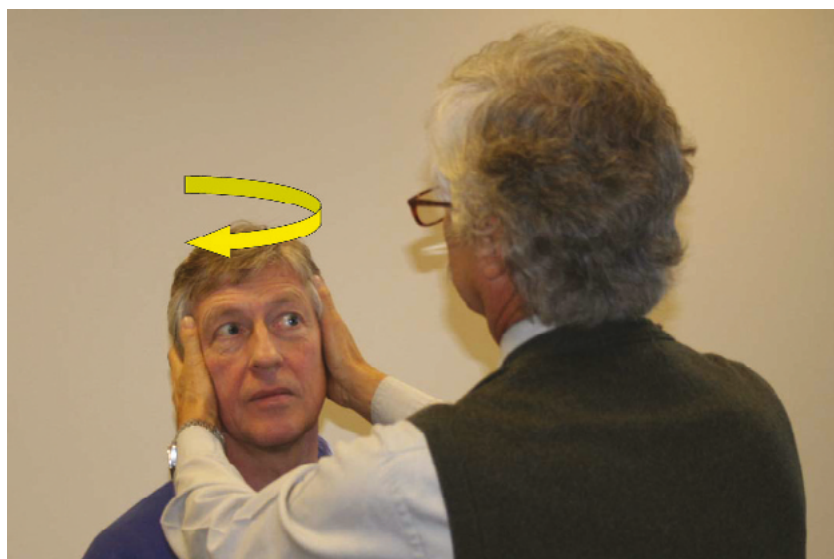

Figure 3

The head impulse or head thrust test. The examiner holds the patient's head and asks him to fixate on her nose. The examiner then delivers a discrete, low amplitude (15–20°), but very fast, head thrust to one side. If the patient's vestibular-ocular reflex (VOR) is intact then, when the head is rotated, the eyes will remain fixated on the examiner's nose. If the VOR is unilaterally impaired then, when the head is rotated the patient's eyes will momentarily lose their fixation on the examiner's nose. The examiner should look for one or more catch up saccades directed back towards the initial fixation point—that is, his nose. The figure shows a left head thrust probing the left horizontal semicircular canal function. Several trials in each direction, right and left, should be carried out in a pseudorandom order.

opposite to that of the observed movement of the sclera (anterior aspect of the globe).

- *Neurological examination:* any clearcut central neurological signs in the presence of a neuro-otological syndrome make lesion localisation relatively easy, particularly when there is brainstem involvement. Isolated cerebellar strokes, however, may mimic a peripheral vestibular syndrome (see below).
- *General examination:* a focussed general examination is also important. For example, if the history and signs suggest a peripheral neuro-otological syndrome, examination of the external auditory meatus is mandatory to look for local pathology such as cholesteatoma, eardrum perforation, discharge, the vesicles of Ramsay-Hunt syndrome, etc. If stroke is considered, a careful cardiovascular examination is required (for example, for atrial fibrillation).

ACUTE ISOLATED VERTIGO

Acute isolated vertigo is usually benign, and indeed a clinician following this rule of thumb will be right most of the time on pure probability grounds. Making a specific diagnosis is important however, as stroke can present with isolated vertigo, and also identifying benign conditions will reassure the patient and ensure expedient management. For example, benign positional paroxysmal vertigo (BPPV) should always be considered, even when acute vertigo apparently persists, because the patient's account of their symptoms may mislead (box 1). It is an important diagnosis both because it is common, and also its identification allows immediate treatment and discharge.^{4, 5}

The important causes of acute isolated vertigo lasting at least several hours that neurologists should be aware of are:

- acute idiopathic unilateral peripheral vestibulopathy ("vestibular neuritis or neuronitis", "labyrinthitis")
- cerebellar stroke
- migrainous vertigo
- "missed" BPPV
- bilateral vestibular failure.

Acute idiopathic unilateral peripheral vestibulopathy

This is the commonest cause of vertigo lasting more than 24 hours during which there are symptoms and signs of unilateral vestibular hypofunction. The syndrome is synonymous with "vestibular neuritis" or "labyrinthitis" (a viral aetiology has been suggested).⁶ Although itself not life threatening, distinguishing vestibular neuritis from stroke for example, is essential not only to avoid missing a serious diagnosis, but also to avoid over-investigation and inappropriate lifelong treatment for secondary stroke prevention.

Typically, patients have a subacute onset over hours, of spinning vertigo. Occasionally the onset is over several minutes but rarely less (when a stroke must be considered). The sensation of vertigo is intense and is almost always associated with nausea and vomiting. Patients see the visual world spinning around them, mainly in a horizontal direction. This visual perception is produced by the slow phase component of the nystagmus (because vision is suppressed during quick-phase eye movements), thus a rightward slow-phase eye movement generates the illusion of leftward visual world movement. The sense of self-movement is present with the eyes closed and is made worse by any head movement and reduced, but rarely fully suppressed, by keeping the head absolutely still. The examination findings have been covered above. Note that, in general, the nystagmus of an acute "vestibular neuritis" settles over several days, *not* due to recovery of function in the affected ear (although this often does recover over weeks to months), but rather to brainstem plasticity (see Gliddon *et al* for review of vestibular plasticity⁷).

Differential diagnoses of an acute unilateral peripheral vestibulopathy

Cerebellar stroke can usually be differentiated by its hyperacute onset—that is, within seconds—although the pace of onset is not always available (for example, if symptoms are present on waking). The head impulse test remains intact (normal) in cerebellar stroke. Occasionally, if the brainstem is not also involved, it can be difficult to distinguish stroke from a peripheral vestibulopathy; where there is any doubt acute neuroimaging is indicated

(we discuss indications for neuroimaging in the next section). In practice, patients with cerebellar infarcts presenting like a vestibular neuritis will typically have a large cerebellar hemispheric stroke and will usually not present to hospital sooner than 24 hours into their history (because they are often treated as an "ear problem" initially); in such cases CT often demonstrates the infarct (or haematoma). Of course, CT negative cases where there is still a suspicion of stroke require MRI.

Migrainous vertigo—this diagnosis is supported by a past history of migraine headache with vertigo. As patients with acute vestibular migraine may have nystagmus with central features,⁸ in an acute first presentation, urgent brain imaging may be required (see below sections on cerebellar stroke and migraine).

Investigation of acute idiopathic unilateral peripheral vestibulopathy

A caloric test is the most useful specialist examination in a patient presenting with what appears to be an acute peripheral vestibulopathy. A recent study found that the bedside iced-water caloric test compared favourably to standard warm water or warm air calorics.⁹ In this study, the authors were able to lower tap water temperature to 4°C by adding ice cubes for about 10 minutes. 2 ml of iced water is injected with a syringe into the external auditory meatus (with prior otoscopy to exclude occlusion by wax, or other local pathology). In a peripheral lesion, iced water on the damaged side either does not cause nystagmus, or has no effect on any spontaneous nystagmus in primary gaze. Electronystagmography does not add greatly to what can be gleaned from a careful clinical examination and caloric testing.

Direct visualisation of an affected vestibular nerve in "vestibular neuritis" has been reported in a single small series with gadolinium enhanced 3T MRI,¹⁰ but imaging in this condition is more of academic interest than of practical utility. Acute neuroimaging is required, however, if a central cause is suspected (for example, cerebellar stroke).

Treatment of acute idiopathic unilateral peripheral vestibulopathy

Recent data have suggested that early intervention with corticosteroids may improve

Box 2 Oculomotor and imaging findings in a patient with acute onset vertigo, nausea vomiting and headache

A 52-year-old man presented 24 hours after the onset of vertigo which came on as he bent down in the shower. The vertigo, which persisted, was severe and accompanied by nausea, vomiting and occipital headache. All symptoms increased with minimal head movement. There was no past history of headache. Clinical examination in the light showed no nystagmus, with normal saccades and smooth pursuit. There was minimal 1° nystagmus on right gaze without visual fixation. There was no on-the-couch limb ataxia and there was too much vertigo and sickness to test gait. Importantly, the head impulse test was normal, although this test provoked vomiting. Acute brain CT (and subsequent MRI) revealed a cerebellar infarct. This patient represents one of the atypical cases who do not have florid cerebellar signs even though they have had a cerebellar stroke. Importantly, the intact head impulse test, despite the disabling vertigo, meant that a peripheral vestibular cause (for example, vestibular neuritis) was an untenable diagnosis. Thus the differential diagnosis lay between migrainous vertigo and a cerebellar stroke. Furthermore, the *new* onset headache in a patient without previous migraine allied to the hyperacute onset vertigo meant that brain imaging was mandatory. Ischaemic strokes involving the cerebellar hemisphere are typically embolic and here the history of a Valsalva manoeuvre (bending down) at vertigo onset was suggestive of paradoxical embolism. A patent foramen ovale with significant right-to-left shunting on Valsalva was demonstrated in this patient who chose to have this closed.

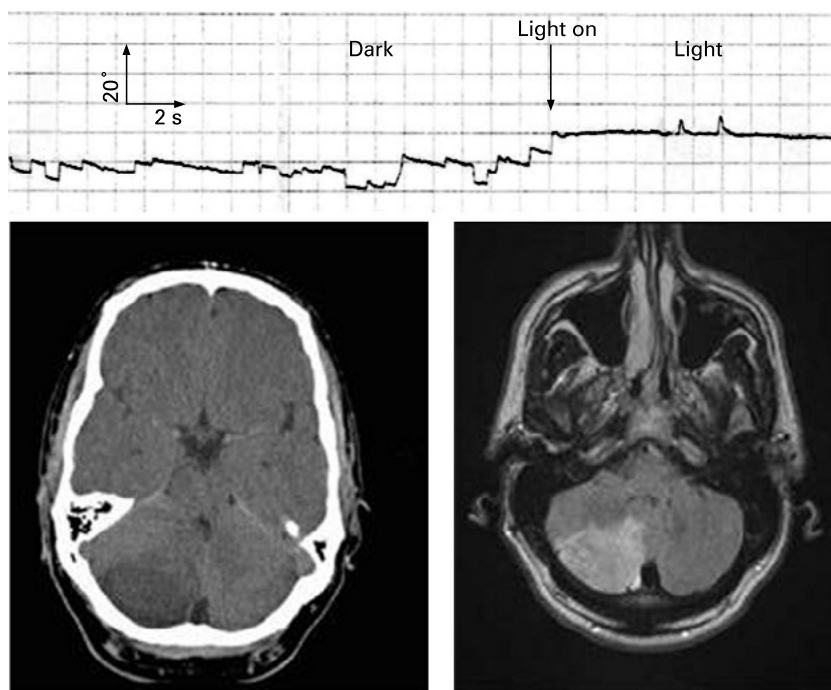


Figure 4 The electronystagmograph of a patient (see clinical vignette in box 2) with a right cerebellar stroke is shown (top) demonstrating a right beating nystagmus (upwards = rightwards on trace) on right gaze (30° from midline) in the dark. Interestingly, this patient was able to suppress his nystagmus in the light (see "light on"). Below shows the initial CT brain and the subsequent MR flair image.

long-term outcome in terms of vestibular function tested by bithermal calorics,^{11, 12} but the key measure of symptomatic outcome (which relates in part to brainstem compensation following a unilateral vestibulopathy) has not been assessed. The utility of steroids in vestibular neuritis therefore remains unclear.

Cerebellar stroke

Vertigo is the commonest symptom in cerebellar stroke.¹³ Moreover, patients with cerebellar hemispheric strokes not also involving the brainstem may complain of vertigo without any other symptoms^{14–19} and also, rarely, there may be no nystagmus or on-the-couch ataxia of the limbs.^{17, 18} Red flags include hyperacute onset vertigo, occipital headache²⁰ or profound gait ataxia.

The clinical approach and neuro-otological examination have been discussed above. A key point to note is that the head impulse test is intact in cerebellar strokes. As there is considerable divergence and pathway redundancy of primary vestibular afferents, theoretically only catastrophic strokes involving the brainstem vestibular nuclei would be sufficient to obliterate the head impulse test, but then the "central versus peripheral" question would be clear-cut on the basis of other symptoms and signs. But note that peripheral combined audiovestibular loss (with an abnormal head impulse test) can occur with vertebrobasilar ischaemia (see "acute vertigo with deafness" below).

A recent reported case illustrates the utility of assessing the VOR (in this case with caloric testing) in what initially appeared to be vestibular neuritis (although the head impulse test was not performed).¹⁹ The normal caloric test alerted the authors to the non-peripheral nature of the case which turned out to be a cerebellar stroke due to vertebral artery dissection. In box 2 and fig 4 we describe a patient with vertigo in whom a negative head impulse test lead us to perform acute brain imaging.

Immediate brain imaging is indicated in suspected cerebellar stroke. Although CT will diagnose some ischaemic strokes and virtually all cerebellar haemorrhages, MRI is more sensitive, particularly with diffusion weighting.²¹ Our criteria for neuro-imaging in acute vertigo are vertigo plus one or more of the following:

- new onset (occipital) headache
- any central neurological symptoms or signs
- acute deafness
- intact head impulse test.

Migrainous vertigo

Migrainous vertigo, although not recognised in the International Headache Society schema, is a commonly diagnosed entity among neuro-otologists. Indeed, in a typical tertiary referral neuro-otology clinic, migrainous vertigo is the commonest new diagnosis. This diagnosis requires clinical suspicion and is one of exclusion; Neuhauser *et al*²² have suggested diagnostic criteria (box 3).

Patients with this syndrome may have dizziness lasting minutes, hours or even more than a day,^{22, 23} and their dizziness ranges from a gentle "rocking-in-a-boat" to a terrifying "merry-go-round" spinning sensation. The diagnosis is easy when patients have concurrent migraine headache with their vestibular symptoms, not surprisingly these cases are less commonly seen in the specialist neuro-otology clinic. The typical patient we see is a migraineur who has noticed a recent increase in headache frequency and, over the same period, developed vestibular episodes, but with headache and vertigo not occurring together. Some patients may have non-headache migrainous symptoms (for example, photophobia) with vertigo or they may have only isolated vertigo. This diagnosis is not widely recognised outside of neuro-otological practice, hence patients are often untreated for years.

Migrainous vertigo is a diagnosis of exclusion and because some patients may have symptoms and signs (including nystagmus)⁸ suggestive of central dysfunction, then acute neuroimaging may be required on first presentation. von Brevern *et al* characterised the oculomotor features of migrainous vertigo within 12 hours of symptom onset.⁸ Of 20 patients assessed, 14 had nystagmus during the attack. Of these patients, 10 had central nystagmus, 3 had peripheral origin nystagmus, and the others remained indeterminate. Importantly, interictal testing in these patients should reveal no (or minor) oculomotor or vestibular abnormality.⁸ These findings⁸ are important both for our understanding of migrainous vertigo from a

Box 3 Neuhauser criteria for migrainous vertigo

Definite

- (1) Episodic vestibular symptoms of at least moderate severity
 - vertigo; positional dizziness and head motion intolerance
- (2) Migraine according to International Headache Criteria
- (3) One or more of the following features during at least two vertigo attacks
 - migrainous headache
 - headache
 - photophobia
 - phonophobia
 - migraine aura
- (4) Other diagnoses excluded by appropriate tests

Probable

- Criterion 1 and 4 as above plus at least ONE of the following:
 - migrainous headache
 - migraine symptoms during vertigo
 - migraine-specific triggers of vertigo (for example, specific food, etc)
 - response to antimigraine drugs

pathophysiological viewpoint, and for the clinician:

- First, that migrainous vertigo is associated with diverse forms of oculomotor dysfunction suggests it may not be a single syndrome with a single underlying pathophysiological process.
- Second, acute migrainous vertigo, particularly on first presentation, may be a diagnostic challenge for the clinician and in this setting other diagnoses (for example, cerebellar or brainstem stroke) may require exclusion with appropriate investigation.

A further problem with the diagnosis of migrainous vertigo is the assumption that migraine always causes vestibular symptoms when these symptoms co-occur. Thus one interpretation of the finding of Radtke *et al*⁴ that 50% of Ménière's patients have migrainous features during acute vertiginous episodes, is that Ménière's disease and migraine share a common pathophysiology. Another possibility is that vestibular activation per se—for example, as during motion sickness—may act as a migraine trigger.²⁵ This is supported by the observation that caloric stimulation may trigger a classical migraine attack in some migraineurs.²⁶

Although there have been no adequate randomised trials of treatment of migrainous

vertigo²⁷⁻²⁹ in the clinic setting, most neuro-otologists use standard antimigraine prophylactic drugs (for example, propranolol, pizotifen and amitriptyline) with reasonable success.

Missed BPPV diagnosis

Patients with acutely symptomatic BPPV continue to be admitted to hospital as emergencies because the spontaneous history provided by the patient may be atypical (often in terms of vertigo duration) and/or the attending physician has failed to perform a Hallpike test. BPPV is the commonest cause of acute vertigo and has such a typical history (that is, position-induced vertigo lasting seconds, typically on lying down and turning over in bed) and findings (torsional nystagmus beating towards the lower ear during the Hallpike manoeuvre) that there is usually little difficulty in making the diagnosis. A recent review⁷ re-emphasises the usefulness of conventional repositioning treatment for this condition.

Bilateral vestibular failure

By far the commonest cause of in-hospital bilateral vestibular failure is aminoglycoside toxicity.^{30, 31} It is generally not appreciated that aminoglycosides have differential effects on vestibular versus cochlear function. Thus gentamicin and streptomycin are primarily vestibulotoxic while amikacin and neomycin are predominantly cochleotoxic. Hence in patients with gentamicin associated vestibular loss, the majority will not be deaf. Indeed, ablation of vestibular function by injection of intra-tympanic gentamicin (in some patients with refractory Ménière's disease) is titrated so that hearing is preserved.

The typical patient³² with aminoglycoside vestibulotoxicity will have been in critical care, often with renal failure. About one in five patients develop episodic vertigo³² lasting several minutes to hours for a few days—which is counterintuitive because one would expect vestibular loss to occur equally on the right and left sides (the vertigo implies a right-left vestibular imbalance). Whatever their origin, the vertiginous episodes wane after a few days as the vestibular function is ablated. The patient's attempts to mobilise and rehabilitate, however, are severely

compromised by poor balance as well as severe oscillopsia on head movement, and this is sometimes compounded by the administration of a long-term vestibular sedative (for example, stemetil). The poor gait often leads to patients being labelled as having had a cerebellar stroke. The diagnosis of vestibulotoxicity must be considered in critically ill patients with "dizziness" and is easily made with the head-impulse test clinically, and confirmed by caloric testing.

Bilateral vestibular failure, which is almost always permanent, can have devastating consequences for the patient's mobility and independence. Functional recovery, which is never complete, is slow (over years). Graded physical activity is important in aiding the recovery of gait and balance. Chronic drug therapy (apart from treating any concurrent migraine) has no role in the rehabilitation of patients with bilateral vestibular failure.

ACUTE VERTIGO WITH DEAFNESS Ménière's disease

Ménière's disease is the commonest cause of acute vertigo with deafness.³³ The diagnostic gold standard is temporal bone histopathology (that is, at postmortem), but day-to-day clinical diagnosis relies on a constellation of symptoms, signs and confirmatory testing.³³⁻³⁵ Typically attacks start with a feeling of fullness in one ear, leading to progressive tinnitus, ipsilateral fluctuating hearing loss and severe vertigo. Examination during an attack shows a peripheral vestibular nystagmus with the head impulse test lateralising the vestibular hypofunction to the symptomatic ear. Over time, there is progressive unilateral audiovestibular loss and as this happens, the severity of the acute attack peters out. Rarely, patients with Ménière's disease may develop very sudden drop attacks without other acute symptoms of Ménière's disease at the same time. In such cases a history of previous typical Ménière's attacks allows the clinician to make the diagnosis.

Vertebrobasilar ischaemia

The advent of neuroimaging, particularly MRI, has allowed an appreciation that sudden hearing loss can occasionally occur in brainstem strokes.³⁶⁻⁴⁴ As this hearing loss is almost always accompanied by vertigo, a

purely peripheral syndrome may be initially considered but the associated brainstem signs in almost every case would suggest central involvement.⁴⁰ In fact, the hearing loss that occurs in brainstem stroke is usually *peripheral* being due to occlusion of the internal auditory artery (IAA) which supplies the membranous labyrinth. This is a branch of the anterior inferior cerebellar artery (AICA) which also supplies the dorsolateral pontomedullary junction and middle cerebellar peduncle. Rarely the IAA is supplied by the medial branch of the posterior inferior cerebellar artery (PICA). Occasionally the hearing loss can be due to a central lesion affecting crossing auditory pathways (lateral lemniscus) of the contralateral dorsolateral upper pons.⁴¹ Additionally, bilateral hearing loss has been reported with vertebrobasilar ischaemia.^{36, 40}

Audiovestibular testing adds little to the diagnosis but may help with prognosis because hearing recovery is less likely with an initial severe hearing loss.⁴⁰ Cochlear dysfunction predominates over retrocochlear loss^{40, 42} but it is unclear if the site of the lesion affects the prognosis for hearing recovery. Overall, however, the prognosis is good with 80% of patients having some degree of hearing recovery in the long term.⁴⁰

A clinically isolated audiovestibular syndrome *without* overt additional neurological signs in the face of MRI evidence of brainstem infarction is rare, accounting for less than 0.35% of vertebrobasilar strokes.⁴⁰ In such cases the area of brainstem infarction is very small, thus explaining the paucity of central signs^{40, 45} (with any prominent audiovestibular symptoms most likely related to "peripheral" ischaemia). Perhaps more common, but still under-recognised because it is so non-specific, is the occurrence of brief (minutes), isolated audiovestibular episodes (mainly vertigo) before a vertebrobasilar stroke.^{40, 45} Grad and Baloh⁴⁵ noted that 60% of patients with brainstem strokes had experienced brief (minutes) isolated vertiginous episodes, presumably representing transient ischaemia either of peripheral or central vestibular structures. It is not known, however, what proportion of all patients with a transient peripheral vestibulopathy subsequently develop a vertebrobasilar stroke (the

PRACTICE POINTS

- Despite the frequency of vertigo as a presenting symptom, many clinicians find the diagnostic approach challenging.
- The first step is an accurate history while being aware of patients' use of ambiguous language to describe their "dizziness".
- If there is any suspicion of benign paroxysmal positional vertigo, or if the diagnosis is unclear, then a Hallpike test should be performed.
- In patients complaining of persisting isolated vertigo, the main differential is between a cerebellar stroke and "vestibular neuritis"—the clinician must therefore first decide whether the lesion is central or peripheral, and the head impulse test is useful in this regard.
- In patients with acute persisting vertigo and headache in whom the head impulse test is normal (that is, a peripheral cause is excluded), the differential diagnosis is between a cerebellar stroke or acute migrainous vertigo and here neuroimaging is mandatory (unless the patient is a previously-investigated migraineur presenting with a typical attack for that patient).
- Ménière's disease, one cause of acute unilateral audiovestibular loss, has such a typical history that diagnosis is straightforward (and is rarely referred to a neurologist).
- A brainstem stroke should be considered in patients with acute audiovestibular loss who do not have typical Ménière's symptoms.

large prospective cohort study to answer this has never been done).

Acoustic neuroma

Acoustic neuromas typically present with gradually progressive unilateral hearing loss and tinnitus. Although reported,⁴⁶ vertigo is rare in uncomplicated acoustic neuroma because the insidious onset allows brainstem mechanisms to almost fully compensate for the progressive peripheral (vestibular) deficit. Many authors have assumed that acute vertigo in acoustic neuroma (which although rare does occur) results from cystic expansion of the tumour, but a large retrospective series⁴⁶ found no difference in the frequency of acute vertiginous episodes between cystic and non-cystic tumours. Rarely, intratumoural haemorrhage into an acoustic neuroma with vertigo has been reported.^{47, 48}

Labyrinthine haemorrhage

Labyrinthine haemorrhage is a rare but increasingly documented cause of acute vertigo and deafness. In 1926, Voss reported a series of infants with perinatal distress and consequent hearing loss and dysequilibrium and in whom postmortem showed endolymphatic haemorrhage in the cochlear and

semicircular canals.⁴⁹ Schuknecht⁵⁰ reported similar autopsy findings in pancytopenic leukaemic patients with acute audiovestibular loss and Whitehead *et al*⁵¹ later reported labyrinthine haemorrhage in a patient with sickle cell disease. Labyrinthine haemorrhage has also been reported in association with antiplatelet and anticoagulant therapy,^{52, 53} cocaine ingestion⁵⁴ and systemic lupus erythematosus.⁵⁵ The diagnosis is made by imaging⁵² which shows hyperintense signal in the membranous labyrinth and cochlea on T2-weighted MRI with no change in signal on contrast administration. The hearing loss and vestibular canal paresis are usually severe and permanent.⁵²

AUTHORS' NOTE

Imperial College Neuro-Otology Unit website: <http://www.imperial.ac.uk/medicine/balance/research>

ACKNOWLEDGEMENTS

This article was reviewed by Richard Metcalfe, Glasgow, UK. BMS is supported by an Academy of Medical Sciences/Health Foundation Clinician Scientist Fellowship. AMB is supported by the Medical Research Council.

REFERENCES

1. Crespi V. Dizziness and vertigo: an epidemiological survey and patient management in the emergency room. *Neurol Sci* 2004;**25**(Suppl 1):S24–5.
2. Moulin T, *et al*. Impact of emergency room neurologists on patient management and outcome. *Eur Neurol* 2003;**50**:207–14.
3. Bronstein AM, Lempert T. *Dizziness: a practical approach to diagnosis and management*. Cambridge Clinical Guides. Cambridge: Cambridge University Press, 2007.
4. White J, Savvides P, Cheria N, *et al*. Canalith repositioning for benign paroxysmal positional vertigo. *Otol Neurotol* 2005;**26**:704–10.
5. Furman JM, Cass SP. Benign paroxysmal positional vertigo. *N Engl J Med* 1999;**341**:1590–6.
6. Baloh RW, Ishiyama A, Wackym PA, *et al*. Vestibular neuritis: clinical-pathologic correlation. *Otolaryngol Head Neck Surg* 1996;**114**:586–92.
7. Gliddon CM, Darlington CL, Smith PF. GABAergic systems in the vestibular nucleus and their contribution to vestibular compensation. *Prog Neurobiol* 2005;**75**:53–81.
8. von Brevin M, Zeise D, Neuhauser H, *et al*. Acute migrainous vertigo: clinical and oculographic findings. *Brain* 2005;**128**:365–74.
9. Schmal F, Lubben B, Weiberg K, *et al*. The minimal ice water caloric test compared with established vestibular caloric test procedures. *J Vestib Res* 2005;**15**:215–24.
10. Karlberg M, Annertz M, Magnusson M. Acute vestibular neuritis visualized by 3-T magnetic resonance imaging with high-dose gadolinium. *Arch Otolaryngol Head Neck Surg* 2004;**130**:229–32.
11. Strupp M, *et al*. Methylprednisolone, valacyclovir, or the combination for vestibular neuritis. *N Engl J Med* 2004;**351**:354–61.
12. Ariyasu L, Byl FM, Sprague MS, *et al*. The beneficial effect of methylprednisolone in acute vestibular vertigo. *Arch Otolaryngol Head Neck Surg* 1990;**116**:700–3.
13. Amarenco P, *et al*. Very small (border zone) cerebellar infarcts. Distribution, causes, mechanisms and clinical features. *Brain* 1993;**116**:161–86.
14. Huang CY, Yu YL. Small cerebellar strokes may mimic labyrinthine lesions. *J Neurol Neurosurg Psychiatry* 1985;**48**:263–5.
15. Amarenco P, Rouillet E, Hommel M, *et al*. Infarction in the territory of the medial branch of the posterior inferior cerebellar artery. *J Neurol Neurosurg Psychiatry* 1990;**53**:731–5.
16. Disher MJ, Telian SA, Kemink JL. Evaluation of acute vertigo: unusual lesions imitating vestibular neuritis. *Am J Otol* 1991;**12**:227–31.
17. Lee H, *et al*. Nodulus infarction mimicking acute peripheral vestibulopathy. *Neurology* 2003;**60**:1700–2.
18. Lee H, Cho YW. A case of isolated nodulus infarction presenting as a vestibular neuritis. *J Neurol Sci* 2004;**221**:117–19.
19. Horii A, Okumura K, Kitahara T, *et al*. Intracranial vertebral artery dissection mimicking acute peripheral vertigo. *Acta Otolaryngol* 2006;**126**:170–3.
20. Kumral E, Bogousslavsky J, Van Melle G, *et al*. Headache at stroke onset: the Lausanne Stroke Registry. *J Neurol Neurosurg Psychiatry* 1995;**58**:490–2.
21. Schaefer PW, Copen WA, Lev MH, *et al*. Diffusion-weighted imaging in acute stroke. *Magn Reson Imaging Clin N Am* 2006;**14**:141–68.
22. Neuhauser H, *et al*. The interrelations of migraine, vertigo, and migrainous vertigo. *Neurology* 2001;**56**:436–41.
23. Cutrer FM, Baloh RW. Migraine-associated dizziness. *Headache* 1992;**32**:300–4.
24. Radtke A, *et al*. Migraine and Ménière's disease: is there a link? *Neurology* 2002;**59**:1700–4.
25. Yen Pik Sang F, Billar J, Gresty MA, *et al*. Effect of a novel motion desensitization training regime and controlled breathing on habituation to motion sickness. *Percept Mot Skills* 2005;**101**:244–56.
26. Seemungal BM, *et al*. Three patients with migraine following caloric-induced vestibular stimulation. *J Neurol* 2006;**253**:1000–1.
27. Dieterich M, Brandt T. Episodic vertigo related to migraine (90 cases): vestibular migraine? *J Neurol* 1999;**246**:883–92.
28. Johnson GD. Medical management of migraine-related dizziness and vertigo. *Laryngoscope* 1998;**108**:1–28.
29. Bikhazi P, Jackson C, Ruckenstein MJ. Efficacy of antimigrainous therapy in the treatment of migraine-associated dizziness. *Am J Otol* 1997;**18**:350–4.
30. Ishiyama G, Ishiyama A, Kerber K, *et al*. Gentamicin ototoxicity: clinical features and the effect on the

- human vestibulo-ocular reflex. *Acta Otolaryngol* 2006;**126**:1057–61.
31. Rinne T, Bronstein AM, Rudge P, et al. Bilateral loss of vestibular function. *Acta Otolaryngol Suppl* 1995;**520**:247–50.
 32. Seemungal BM, Bronstein AM. Aminoglycoside toxicity: vestibular function is also vulnerable. *BMJ* 2007;**335**:952.
 33. Minor LB, Schessel DA, Carey JP. Ménière's disease. *Curr Opin Neurol* 2004;**17**:9–16.
 34. Monsell EM. New and revised reporting guidelines from the Committee on Hearing and Equilibrium. American Academy of Otolaryngology-Head and Neck Surgery Foundation, Inc. *Otolaryngol Head Neck Surg* 1995;**113**:176–8.
 35. Merchant SN, Adams JC, Nadol JB Jr. Pathophysiology of Ménière's syndrome: are symptoms caused by endolymphatic hydrops? *Otol Neurotol* 2005;**26**:74–81.
 36. Khurana RK, O'Donnell PP, Suter CM, et al. Bilateral deafness of vascular origin. *Stroke* 1981;**12**:521–3.
 37. Lownie SP, Parnes LS. Isolated vestibulocochlear dysfunction of central or peripheral vascular origin. *Laryngoscope* 1991;**101**:1339–42.
 38. Biavati MJ, Gross JD, Wilson WR, et al. Magnetic resonance imaging evidence of a focal pontine ischemia in sudden hearing loss and seventh nerve paralysis. *Am J Otol* 1994;**15**:250–3.
 39. Mort DJ, Bronstein AM. Sudden deafness. *Curr Opin Neurol* 2006;**19**:1–3.
 40. Lee H, Baloh RW. Sudden deafness in vertebrobasilar ischemia: clinical features, vascular topographical patterns and long-term outcome. *J Neurol Sci* 2005;**228**:99–104.
 41. Doyle KJ, Fowler C, Starr A. Audiologic findings in unilateral deafness resulting from contralateral pontine infarct. *Otolaryngol Head Neck Surg* 1996;**114**:482–6.
 42. Lee H, et al. Sudden deafness and anterior inferior cerebellar artery infarction. *Stroke* 2002;**33**:2807–12.
 43. Raupp SF, Jellema, Sluzewski M, et al. Sudden unilateral deafness due to a right vertebral artery dissection. *Neurology* 2004;**62**:1442.
 44. Yi HA, et al. Sudden deafness as a sign of stroke with normal diffusion-weighted brain MRI. *Acta Otolaryngol* 2005;**125**:1119–21.
 45. Grad A, Baloh RW. Vertigo of vascular origin. Clinical and electronystagmographic features in 84 cases. *Arch Neurol* 1989;**46**:281–4.
 46. Sugimoto T, et al. Relationship between cystic change and rotatory vertigo in patients with acoustic neuroma. *Acta Otolaryngol Suppl* 2000;**542**:9–12.
 47. Ihara T, et al. [Case of acoustic neurinoma with intratumoral hemorrhage extending to cerebellar hemisphere]. *No Shinkei Geka* 1984;**12**:1101–5.
 48. Schlieter M, et al. Hemorrhagic acoustic schwannoma: radiological and histopathological findings. *J Neuroradiol* 2005;**32**:210–12.
 49. Voss O. *Kinderheilk*. In: Holden HB, Schuknecht MD. Distribution pattern of blood in the inner ear following spontaneous subarachnoid haemorrhage. *J Laryngol Otol* 1968;**82**:321–9.
 50. Schuknecht HF, Igarashi M, Chasin WD. Inner ear hemorrhage in leukaemia. A case report. *Laryngoscope* 1965;**75**:662–8.
 51. Whitehead RE, MacDonald CB, Melhem ER, et al. Spontaneous labyrinthine hemorrhage in sickle cell disease. *AJNR Am J Neuroradiol* 1998;**19**:1437–40.
 52. Shinohara S, et al. Clinical features of sudden hearing loss associated with a high signal in the labyrinth on unenhanced T1-weighted magnetic resonance imaging. *Eur Arch Otorhinolaryngol* 2000;**257**:480–4.
 53. Vellin JF, et al. [Labyrinthine hemorrhage caused by anticoagulant therapy]. *Ann Otolaryngol Chir Cervicofac* 2005;**122**:194–7.
 54. Nicoucar K, et al. Intralabyrinthine haemorrhage following cocaine consumption. *Acta Otolaryngol* 2005;**125**:899–901.
 55. Sugiura M, et al. Inner ear hemorrhage in systemic lupus erythematosus. *Laryngoscope* 2006;**116**:826–8.

Early Diagnosis and Management of Acute Vertigo from Vestibular Migraine and Ménière's Disease



Barry Seemungal, BSc, MB BCH, PhD, FRCP^{a,*}, Diego Kaski, MBBS, PhD^a,
Jose Antonio Lopez-Escamez, MD, PhD^b

KEYWORDS

- Vestibular disorders • Vertigo • Hearing loss • Tinnitus • Migraine
- Ménière's disease

KEY POINTS

- Vestibular migraine (VM) is second only to benign paroxysmal positional vertigo as the most common cause of acute episodic vestibular symptoms.
- Ménière's disease (MD) is uncommon; however, accurate diagnosis (or its exclusion) enables the correct management of patients with acute episodic vestibular symptoms.
- A focused neurologic examination can exclude other sinister causes such as stroke.
- Although most cases can be treated in the emergency room (ER), some patients may require a brief hospital admission to control symptoms.

VESTIBULAR MIGRAINE

Case Scenario

A 46-year old woman presented with a 2-hour history of sudden onset and continuous vertigo (a feeling that her head was spinning) and severe nausea but mild occipital headache. During the previous 4 months, she noted weekly uncomfortable headaches occasionally accompanied by photophobia, bilateral tinnitus, and aural fullness. In her late teens to mid-20s, she suffered from monthly severe headaches with nausea, vomiting, and sometimes severe dizziness, lasting up to 2 days. On this occasion, the clinical examination was entirely normal, including a normal gait. MRI of the brain showed normal findings. She was treated with intravenous prochlorperazine and oral aspirin and discharged with a prescription of oral propranolol 20 mg twice a day with a plan for a clinic follow-up in 8 weeks.

^a Division of Brain Sciences, Charing Cross Hospital, Imperial College London, London, W6 8RF, UK; ^b Otolaryngology and Neurotology Group CTS495, Department of Otolaryngology, Hospital de Poniente, El Ejido, Almería, Spain

* Corresponding author.

E-mail address: b.seemungal@imperial.ac.uk

Prevalence and Pathophysiologic Mechanisms

VM has an estimated lifetime prevalence of approximately 3.2%, making it one of the most common vestibular disorders.¹ The estimated 1-year prevalence is 0.89% across the population² and 5% in women aged 40 to 54 years.³

The current understanding and hypotheses underlying the pathophysiology of VM stem from genetic and in vitro studies, animal models, and human clinical studies of migraine.^{4–8} A key mechanism identified in migraine pathophysiology is activation of the trigeminovascular system. The labyrinthine vessels are innervated by trigeminal nerve terminals, which, combined with the presence of vasoactive neuropeptides in the perivascular afferent terminals of these trigeminal fibers, support the notion that the vascular, neuroinflammatory, and central neural mechanisms implicated in migraine are common to the central vestibular mechanisms and to the inner ear.^{9,10} This notion may explain why there exists a reciprocal interaction between peripheral vestibular deficits and VM.^{11,12}

Neuroanatomic regions implicated

Numerous brain regions and networks have been implicated in the pathogenesis of VM, including the posterior and anterior insula, orbitofrontal cortex, and the posterior and anterior cingulate gyri.^{13–15} The perceptual correlate of VM encompasses vestibular thalamocortical networks that produce perceptual responses to vestibular, visual, proprioceptive, and somatosensory afferent inputs. This cognitive-behavioral domain includes frontal and parietal cortical pathways related to premonitory symptoms associated with balance control.¹⁶

Brainstem pathways have been implicated in the generation of somatic (eg, vestibular ocular and vestibular spinal reflexes) and visceral (vestibular sympathetic and parasympathetic) motor responses.¹⁷ In the context of spontaneous migraine attacks, these vestibular sensorimotor responses seem to be modulated by the cerebellum.¹⁸ Functional neuroimaging techniques suggest that VM relates to abnormal brain sensitization leading to a dysmodulation of multimodal sensory integration and processing resulting in a vestibulothalamocortical dysfunction.¹⁹

At the cellular level, it has been identified in animal models of migraine that activation of trigeminal ganglion innervation within cerebral and meningeal vasculature induces a trigeminovascular reflex-mediated vasodilation of meningeal vessels via the sphenopalatine ganglion.²⁰ Similar events have been observed in the murine inner ear.²¹ The prevalence of VM suggests that multiple functional variants may confer a genetic susceptibility leading to a dysregulation of excitatory-inhibitory balance in brain structures involved in the processing of sensory information, vestibular inputs, and pain.¹⁹

At present, there is no convincing evidence to explain how migraine could cause an apparent episodic inner ear or central vestibular dysfunction as observed during acute VM.²² Transient vasospasm of the blood supply to the inner ear (via the internal auditory artery) is one proposed hypothesis. Conversely, a transient episode of inner ear ischemia (from cerebrovascular disease) could trigger a migraine, a tenable possibility given the intimate link between the vestibular apparatus and the trigeminovascular system. Another explanation is the neurogenic hypothesis, for example, via a channelopathy that can manifest with migraines,²³ and such syndromes are associated with episodic neurologic dysfunction. A channelopathy hypothesis, as a common underlying mechanism, could explain the epidemiologic link between migraine and MD, perhaps also explaining the symptomatic overlap between MD and VM.²⁴

Definitions and Diagnostic Criteria (Differentiation from transient ischaemic attack [TIA] + Approach to Initial Diagnosis)

The diagnosis of VM requires clinical suspicion. Recently, a consensus paper was published on the criteria for VM (**Box 1**).²⁷ The consensus acknowledges that migraine may present with mainly vestibular symptoms and hence is called VM. The criteria recognize the bidirectional relationship between migraine and vertigo (see note h in **Box 1**), that is, acute vertigo of any origin can trigger migraine features, including headache. Hence, patients with a primary vestibular problem who are also migraineurs, could at first glance conform to the VM criteria.

An important differential diagnosis of acute VM is of a cerebellar stroke not involving the brainstem. Although VM may present in a myriad of ways, with examination signs mimicking an acute or central peripheral vestibular syndrome,²² the only real differential diagnosis of cerebellar stroke not involving the brainstem is an acute VM. Such strokes are typically embolic²⁸ and present with thunderclap onset vertigo (often severe) with nausea, vomiting, and imbalance on walking, and half the cases have occipital headache. The examination in such cerebellar strokes may show a direction-changing nystagmus on gaze testing and/or a skew deviation (see article elsewhere in this issue), both features of a central lesion. Some cases of cerebellar stroke not involving the brainstem may present with little or no eye signs.²⁹ The head impulse test is normal in 90% of cerebellar strokes.³⁰ Irrespective of the head impulse test, gait ataxia is a red flag directing the clinician to perform emergency neuroimaging.

In a patient presenting with vertigo for the first time, it may not be possible to clinically differentiate between acute VM and an acute cerebellar stroke because both may present with severe vertigo, nausea, vomiting, posterior headache, gait ataxia, few ocular signs, and a preserved head impulse test. In such cases, immediate brain MRI should be performed and possibly repeated if the initial scan is normal and the clinical suspicion is high. A history of multiple similar episodes over a prolonged period is likely to represent VM and not stroke however, on first presentation, such patients should be investigated with neuroimaging if the clinical picture warrants it.

In conclusion, although a cerebellar stroke not involving the brainstem may present in a manner identical to VM, it can be reliably distinguished from an acute peripheral vestibular syndrome (see article elsewhere in this issue). Hence, it perhaps is most important to consider the red flags for investigating such cases. VM can present with signs of a peripheral vestibular lesion; however, the need for immediate investigation is less pressing. The diagnosis of VM can be definitively made in cases presenting with repeated episodes (that conform to the VM diagnostic criteria) whereby no other vestibular diagnosis is forthcoming and in whom there are no interictal abnormalities. In contrast, patients with MD typically display persistent sensorineural hearing loss and impaired peripheral vestibular function in the affected ear even between attacks.

Bedside and Laboratory Diagnostic Tests

History

In acute VM, there may be no headache complaint; however, if present, it is important to characterize the type of headache during the attack. In addition, the clinician should ask about previous headache history. The headache interview should include specific questions concerning location (unilateral in migraine), pulsating quality, moderate or severe intensity, aggravation by activity, and sensitivity to light and sound. Although visual symptoms may occur, one would not expect any sensory deficit,

Box 1**Vestibular migraine diagnostic criteria****1. Definite vestibular migraine**

- a. At least 5 episodes with vestibular symptoms^a of moderate or severe intensity,^b lasting 5 minutes to 72 hours^c
- b. Current or previous history of migraine with or without aura according to the International Classification of Headache Disorders (ICHD)^d
- c. One or more migraine features with at least 50% of the vestibular episodes^e:
 - i Headache with at least 2 of the following: (1) one-sided location, (2) pulsating quality, (3) moderate or severe pain intensity, (4) aggravation by routine physical activity
 - ii Photophobia and phonophobia^f
 - iii Visual aura^g
- d. Not better accounted for by another vestibular or ICHD diagnosis^h

2. Probable vestibular migraine

- a. At least 5 episodes with vestibular symptoms^a of moderate or severe intensity,^b lasting 5 minutes to 72 hours^c
- b. Only one of the criteria b and c for vestibular migraine is fulfilled (migraine history or migraine features during the episode)
- c. Not better accounted for by another vestibular or ICHD diagnosis^h

^a Vestibular symptoms, as defined by the Barany Society's Classification of Vestibular Symptoms²⁵ and qualifying for a diagnosis of vestibular migraine, include (1) spontaneous vertigo including internal vertigo, a false sensation of self-motion, and external vertigo, a false sensation that the visual surround is spinning or flowing; (2) positional vertigo, occurring after a change of head position; (3) visually induced vertigo, triggered by a complex or large moving visual stimulus; (4) head motion-induced vertigo, occurring during head motion; and (5) head motion-induced dizziness with nausea. Dizziness is characterized by a sensation of disturbed spatial orientation. Other forms of dizziness are currently not included in the classification of vestibular migraine.

^b Vestibular symptoms are rated "moderate" when they interfere with but do not prohibit daily activities and "severe" if daily activities cannot be continued.

^c Duration of episodes is highly variable: About 30% of patients have episodes lasting minutes, 30% have attacks for hours, and another 30% have attacks for several days. The remaining 10% have attacks lasting seconds only, which tend to occur repeatedly during head motion, visual stimulation, or after changes of head position. In these patients, episode duration is defined as the total period during which short attacks recur. At the other end of the spectrum, there are patients who may take 4 weeks to fully recover from an episode. However, the core episode rarely exceeds 72 hours.

^d Migraine categories 1.1 and 1.2 of the ICDH.²⁶

^e One symptom is sufficient during a single episode. Different symptoms may occur during different episodes. Associated symptoms may occur before, during, or after the vestibular symptoms.

^f Phonophobia is defined as sound-induced discomfort. It is a transient and bilateral phenomenon that must be differentiated from recruitment, which is often unilateral and persistent. Recruitment leads to an enhanced perception and often distortion of loud sounds in an ear with decreased hearing.

^g Visual auras are characterized by bright scintillating lights or zigzag lines, often with a scotoma that interferes with reading. Visual auras typically expand from 5 to 20 minutes and last for less than 60 minutes. They are often, but not always, restricted to 1 hemifield. Other types of migraine aura, for example, somatosensory or dysphasic aura, are not included as diagnostic criteria because their phenomenology is less specific and most patients also have visual auras.

^h History and physical examinations do not suggest another vestibular disorder, such as a disorder is considered but ruled out by appropriate investigations, or such disorder is present as a comorbid or independent condition, but episodes can be clearly differentiated. Migraine attacks may be induced by vestibular stimulation.¹¹ Therefore, the differential diagnosis should include other vestibular disorders complicated by superimposed migraine attacks.

speech/language symptoms, or motor weakness in VM, although virtually any combination of transient neurologic features is possible as part of an acute migraine syndrome. Although hemorrhagic stroke is widely known to be associated with headache, it is less well recognized that occipital headache is a feature in one-third of acute posterior circulation ischemic stroke.³¹ Hence, the presence of acute headache does not immediately include a diagnosis of VM to the exclusion of stroke.

The examination

The examination (see article elsewhere in this issue) should include an assessment of cranial nerves, eye movements including the cover test, vergence, spontaneous and gaze-evoked nystagmus assessment, saccades, smooth pursuit, and the head impulse test. When the neurologic examination indicates central dysfunction, then immediate neuroimaging is indicated looking for brainstem or cerebellar pathology. If brain MRI shows normal findings and the clinical suspicion is high, then the patient should be clinically monitored and reimaged because early MRI can miss acute brainstem infarction.

Laboratory test

Blood glucose levels are determined.

Immediate Treatment Options

There are no robust clinical trial data for the immediate treatment of VM; however, treatment is primarily symptomatic and hence follows standard medical practice such as fluid replacement for vomiting (eg, intravenous saline) and antiemetics for nausea (prochlorperazine, metoclopramide, or cyclizine). It is advisable to avoid excessive sedation, which precludes reliable monitoring of the neurologic state. In patients in whom hemorrhagic cerebellar stroke has been excluded, a single enteral dose of aspirin, 900 to 1200 mg, or nonsteroidal anti-inflammatory drug (eg, ibuprofen 400–800 mg) can be given for headache.

Triage and Disposition

Prophylaxis

In some patients, migraine triggers can be identified, such as lack of sleep or food, psychological stress, or certain foodstuffs (eg, chocolate or cheese). Lifestyle adjustments can reduce attack frequency by avoiding such triggers. In some patients, there are no obvious triggers, and when attacks are frequent, standard practice includes the use of a daily dose of an antimigraine drug to reduce the frequency of attacks. The evidence supporting the use of these drugs in VM is limited, but commonly used drugs include β -blockers (propranolol), tricyclic antidepressants (amitriptyline), antiepileptics (valproate, topiramate), and antiserotonergics (pizotifen).

Patients with poorly controlled VM often develop chronic maladaptive symptoms such as visually induced dizziness. The authors' practice is to first treat these patients with antimigraine prophylactic drugs and then add vestibular rehabilitation exercises after if not fully recovered.

MÉNIÈRE'S DISEASE

Case Scenario

A 39-year-old man presented to the ER with severe vertigo with nausea and vomiting. Four hours previously he had woken to find that there was a fullness in his right ear. An hour later, there was a ringing noise in his right ear followed by a distortion of hearing on the right. He had a gradual build-up of feeling that he was spinning around. Eventually, he began to see the room spin around and started to vomit. He came to the ER.

The patient reported that he had 2 similar attacks during the past year. On this occasion, the examination showed a left beating third-degree vestibular nystagmus but with a normal head impulse test. Twenty minutes later, the patient was reexamined, but now the nystagmus was beating to the patient's right. The patient was treated with parenteral prochlorperazine. His vertigo and nausea settled after 30 minutes. The patient was observed for a further 4 hours and then eventually allowed to go home with a 2-day supply of prochlorperazine.

Prevalence and Pathophysiologic Mechanisms

The prevalence of MD is 5 to 500 per 100,000 habitants, and familial MD is around 9% of cases.³² Human temporal bone studies have linked MD symptoms to the accumulation of endolymph within the cochlear duct (scala media) and the sacculus in the inner ear. It is thought that this endolymphatic hydrops begins with derangement of the ionic composition of the scala media. However, current data support the hypothesis that endolymphatic hydrops is an epiphenomenon associated with a variety of inner ear disorders,³³ and familial clustering indicates that genetics and environmental factors contribute to its development.³²

Definitions and Diagnostic Criteria (Differentiation from TIA + Approach to Initial Diagnosis)

MD is characterized by recurrent attacks of spontaneous vertigo associated with hearing loss and tinnitus in the same ear.³⁴ Aural fullness and headache can be found during the attacks. The International Classification for Vestibular Disorders Committee of the Barany Society has developed consensus diagnostic criteria with American Academy of Otolaryngology – Head and Neck Surgery, European Academy of Otology & Neuro-Otology, Japan Society for Equilibrium Research, and the Korean Balance Society.³⁵ These criteria define 2 categories: definite and probable MD (Box 2).

Bedside and Laboratory Diagnostic Tests

A national survey in the United States showed that only 26.9% to 46.7% of otolaryngologists relied on history, physical examination, and audiometry alone to diagnose MD. Adjunctive tests are thus helpful to support the clinical diagnosis, particularly given the high rates of misdiagnosis (mainly overdiagnosis) of MD.

A focused eye movement examination should evaluate the presence of spontaneous and gaze-evoked nystagmus, the integrity of the vestibular ocular reflex

Box 2
Ménière's disease diagnostic criteria

Definite Ménière's disease

1. Two or more spontaneous episodes of vertigo, each lasting 20 minutes to 12 hours
2. Audiometrically documented low- to medium-frequency sensorineural hearing loss in the affected ear on at least 1 occasion before, during, or after one of the episodes of vertigo
3. Fluctuating aural symptoms (hearing, tinnitus, or fullness) in the affected ear
4. Not better accounted for by another vestibular diagnosis

Probable Ménière's disease

1. Two or more episodes of vertigo or dizziness, each lasting 20 minutes to 24 hours
2. Fluctuating aural symptoms (hearing, tinnitus, or fullness) in the reported ear
3. Not better accounted for by another vestibular diagnosis

(head impulse test), pursuit, and saccadic eye movements. Positional maneuvers should be performed in any patient presenting with episodic dizziness to exclude benign paroxysmal positional vertigo.

A bedside assessment of hearing may be insufficient to identify hearing loss, and an audiogram should be obtained in any patient with suspected MD, including tympanometry. Hearing loss is usually in the low-frequency range, and MD can result in marked intolerance to loud sounds.³⁶ Hearing and tinnitus fluctuate in the early stages of disease, but in the later stages they may become permanent.

Brain imaging, ideally with MRI, helps one to exclude secondary causes of Ménière's syndrome and posterior fossa lesions that may present with progressive hearing loss and vertigo. Moreover, endolymphatic hydrops in Ménière's disease may be visualized on high-resolution MRI after transtympanic gadolinium injection.³⁷

During electrocochleography (EChG), an evoked summating potential (SP) and action potential (AP) are recorded in response to click or tone burst stimuli recorded by an intratympanic or extratympanic electrode. In a large case series, increased SP/AP ratio (>0.4) was found in 72% of patients with a clinical diagnosis of MD,³⁸ and the yield of the test increases with disease severity and duration. Although not widely available in routine clinical practice, EChG can be of use, particularly when there exists diagnostic uncertainty.³⁹

The cervical vestibular evoked myogenic potential (cVEMP) is a short latency inhibitory potential of the ipsilateral sternocleidomastoid muscle evoked by a brief and loud (>85 dB) monaural click or tone burst stimuli.⁴⁰ The cVEMP is thought to be of saccular origin and mediated by the inferior vestibular nerve.⁴⁰ Patients with MD have increased cVEMP thresholds or absent VEMPs compared with controls.⁴¹ Consistent with its otolithic basis, abnormal cVEMPs are more common in patients with Tumarkin crises⁴² and also seen in 27% of the contralateral asymptomatic ears of patients with MD.⁴³

The role of oculography in the diagnosis of MD is limited but may help differentiate MD from central causes of vertigo. Although pathologic canal paresis is present in 42% to 73% of patients with MD,⁴⁴ complete loss of function is rare, and therefore, only a minority of patients have an impaired head impulse test.⁴⁴ Caloric testing may help in the assessment of contralateral function before an ablative procedure, evaluation of postablative residual function, and identification of patients with preserved ipsilesional canal function where nondestructive treatment options may be preferred.⁴⁵

Immediate Treatment Options (Including Manipulative and Pharmacologic [Rehabilitative])

In an acute attack of MD, the treatment is symptomatic. Nausea and vomiting can be treated with standard antiemetics such as phenothiazines (prochlorperazine), antihistamines (cyclizine), and antimuscarinic drugs (scopolamine). It is reasonable to provide a benzodiazepine during the acute attack to alleviate anxiety.

Triage and Disposition

The natural history of Ménière's disease is unpredictable, although typically unilateral at onset, whereby the frequency of attacks first increases, then decreases. Bilateral involvement is more common with increasing disease duration: 15% in the first 2 years, 35% after 10 years, and up to 47% after 20 years.⁴⁶

Various interventions are used to reduce the number of attacks or progression of audiovestibular failure in MD, although none have a strong evidence base.³⁴ One intervention is dietary salt restriction (daily sodium intake of <2 g/d), which is thought to reduce the osmotic build-up of pressure in the endolymphatic compartment. Using

a similar logic, diuretics are also prescribed for MD, although a Cochrane review did not support their use.⁴⁷ High-dose betahistine may have a prophylactic effect on the frequency of attacks of MD, at least in the first year,⁴⁸ although its effect on vestibular and audiological function is unknown. Although the evidence remains scarce, systemic steroids should be considered in patients with a comorbid autoimmune condition especially if there is bilateral sensorineural hearing loss.⁴⁹ There is also weak evidence that intratympanic dexamethasone may reduce attacks of Ménière's disease and without significant systemic side effects.^{50,51} In patients in whom there is significant audiovestibular loss in the affected ear but with continuing severe attacks, subablative therapy with intratympanic gentamicin may be effective in curtailing attacks.³⁴ Finally, the role of vestibular rehabilitation in the acute phase of the disease is controversial, given the fluctuating nature of vestibular symptoms in these patients. Nevertheless, there is evidence to suggest that vestibular rehabilitation across the spectrum of MD improves both subjective and objective balance function.⁵²

When to refer

Specialist referral is indicated in patients with clinically suspected MD for diagnostic purposes. Such patients may also require referral for consideration of preventative strategies, for medical and surgical intervention where symptoms are persistent or severe, and to ensure the involvement of a multidisciplinary team, including otolaryngologists, neuro-otologists, physiotherapists, and audiologists. Given the unpredictable and disabling nature of the condition, psychological support can play an important role in long-term management to improve quality of life.

REFERENCES

1. Lempert T, Neuhauser H. Epidemiology of vertigo, migraine and vestibular migraine. *J Neurol* 2009;256(3):333–8.
2. Neuhauser HK, Radtke A, von Brevern M, et al. Migrainous vertigo: prevalence and impact on quality of life. *Neurology* 2006;67(6):1028–33.
3. Hsu LC, Wang SJ, Fuh JL. Prevalence and impact of migrainous vertigo in mid-life women: a community-based study. *Cephalalgia* 2011;31(1):77–83.
4. Goadsby PJ, Lipton RB, Ferrari MD. Migraine – current understanding and treatment. *N Engl J Med* 2002;346(4):257–70.
5. Pietrobon D. Migraine: new molecular mechanisms. *Neuroscientist* 2005;11(4):373–86.
6. Pietrobon D, Moskowitz MA. Pathophysiology of migraine. *Annu Rev Physiol* 2013;75:365–91.
7. Vecchia D, Pietrobon D. Migraine: a disorder of brain excitatory-inhibitory balance? *Trends Neurosci* 2012;35(8):507–20.
8. von Brevern M, Radtke A, Clarke AH, et al. Migrainous vertigo presenting as episodic positional vertigo. *Neurology* 2004;62(3):469–72.
9. May A, Goadsby PJ. The trigeminovascular system in humans: pathophysiologic implications for primary headache syndromes of the neural influences on the cerebral circulation. *J Cereb Blood Flow Metab* 1999;19(2):115–27.
10. Vass Z, Dai CF, Steyger PS, et al. Co-localization of the vanilloid capsaicin receptor and substance P in sensory nerve fibers innervating cochlear and vertebral-basilar arteries. *Neuroscience* 2004;124(4):919–27.
11. Murdin L, Davies RA, Bronstein AM. Vertigo as a migraine trigger. *Neurology* 2009;73(8):638–42.
12. Seemungal B, Rudge P, Davies R, et al. Three patients with migraine following caloric-induced vestibular stimulation. *J Neurol* 2006;253(8):1000–1.

13. Bucher SF, Dieterich M, Wiesmann M, et al. Cerebral functional magnetic resonance imaging of vestibular, auditory, and nociceptive areas during galvanic stimulation. *Ann Neurol* 1998;44(1):120–5.
14. Dieterich M, Brandt T. Functional brain imaging of peripheral and central vestibular disorders. *Brain* 2008;131(Pt 10):2538–52.
15. Fasold O, von Brevern M, Kuhberg M, et al. Human vestibular cortex as identified with caloric stimulation in functional magnetic resonance imaging. *Neuroimage* 2002;17(3):1384–93.
16. Furman JM, Marcus DA, Balaban CD. Vestibular migraine: clinical aspects and pathophysiology. *Lancet Neurol* 2013;12(7):706–15.
17. Holstein GR, Friedrich VL Jr, Kang T, et al. Direct projections from the caudal vestibular nuclei to the ventrolateral medulla in the rat. *Neuroscience* 2011;175:104–17.
18. Afridi SK, Giffin NJ, Kaube H, et al. A positron emission tomographic study in spontaneous migraine. *Arch Neurol* 2005;62(8):1270–5.
19. Espinosa-Sánchez JM, Lopez-Escamez JA. New insights into pathophysiology of vestibular migraine. *Front Neurol* 2015;6:12.
20. Iadecola C. From CSD to headache: a long and winding road. *Nat Med* 2002;8(2):110–2.
21. Koo JW, Balaban CD. Serotonin-induced plasma extravasation in the murine inner ear: possible mechanism of migraine-associated inner ear dysfunction. *Cephalalgia* 2006;26(11):1310–9.
22. von Brevern M, Zeise D, Neuhauser H, et al. Acute migrainous vertigo: clinical and oculographic findings. *Brain* 2005;128(Pt 2):365–74.
23. Seemungal BM, Gresty MA, Bronstein AM. The endocrine system, vertigo and balance. *Curr Opin Neurol* 2001;14(1):27–34.
24. Lopez-Escamez JA, Dlugaičzyk J, Jacobs J, et al. Accompanying symptoms overlap during attacks in Ménière's disease and vestibular migraine. *Front Neurol* 2014;5:265.
25. Bisdorff A, Von Brevern M, Lempert T, et al. Classification of vestibular symptoms: towards an international classification of vestibular disorders. *J Vestib Res* 2009;19(1–2):1–13.
26. Headache Classification Subcommittee of the International Headache Society. The international classification of headache disorders: 2nd edition. *Cephalalgia* 2004;24(Suppl 1):9–160.
27. Lempert T, Olesen J, Furman J, et al. Vestibular migraine: diagnostic criteria. *J Vestib Res* 2012;22(4):167–72.
28. Amarenco P, Lévy C, Cohen A, et al. Causes and mechanisms of territorial and nonterritorial cerebellar infarcts in 115 consecutive patients. *Stroke* 1994;25(1):105–12.
29. Seemungal BM. Neuro-otological emergencies. *Curr Opin Neurol* 2007;20(1):32–9.
30. Newman-Toker DE, Kattah JC, Alvernia JE, et al. Normal head impulse test differentiates acute cerebellar strokes from vestibular neuritis. *Neurology* 2008;70(24 Pt 2):2378–85.
31. Searls DE, Pazdera L, Korbel E, Vysata O, Caplan LR. Symptoms and signs of posterior circulation ischemia in the new England medical center posterior circulation registry. *Arch Neurol* 2012;69(3):346–51.
32. Requena T, Espinosa-Sanchez JM, Cabrera S, et al. Familial clustering and genetic heterogeneity in Ménière's disease. *Clin Genet* 2014;85(3):245–52.
33. Merchant SN, Adams JC, Nadol JB Jr. Pathophysiology of Ménière's syndrome: are symptoms caused by endolymphatic hydrops? *Otol Neurotol* 2005;26(1):74–81.

34. Harcourt J, Barraclough K, Bronstein AM. Ménière's disease. *BMJ* 2014;349:g6544.
35. Lopez-Escamez JA, Carey J, Chung WH, et al. Diagnostic criteria for Ménière's disease. *J Vest Res* 2015;25(1):1–7.
36. Hood JD. Audiological considerations in Ménière's disease. *ORL J Otorhinolaryngol Relat Spec* 1980;42(1–2):77–90.
37. Carfrae MJ, Holtzman A, Eames F, et al. 3 Tesla delayed contrast magnetic resonance imaging evaluation of Ménière's disease. *Laryngoscope* 2008;118(3):501–5.
38. Ge X, Shea JJ Jr. Transtympanic electrocochleography: a 10-year experience. *Otol Neurotol* 2002;23(5):799–805.
39. Kim HH, Wiet RJ, Battista RA. Trends in the diagnosis and the management of Ménière's disease: results of a survey. *Otolaryngol Head Neck Surg* 2005;132(5):722–6.
40. Curthoys IS, Vulovic V, Burgess AM, et al. Neural basis of new clinical vestibular tests: otolithic neural responses to sound and vibration. *Clin Exp Pharmacol Physiol* 2014;41(5):371–80.
41. Rauch SD, Zhou G, Kujawa SG, et al. Vestibular evoked myogenic potentials show altered tuning in patients with Ménière's disease. *Otol Neurotol* 2004;25(3):333–8.
42. Timmer FC, Zhou G, Guinan JJ, et al. Vestibular evoked myogenic potential (VEMP) in patients with Ménière's disease with drop attacks. *Laryngoscope* 2006;116(5):776–9.
43. Lin MY, Timmer FC, Oriel BS, et al. Vestibular evoked myogenic potentials (VEMP) can detect asymptomatic saccular hydrops. *Laryngoscope* 2006;116(6):987–92.
44. Park HJ, Migliaccio AA, Della Santina CC, et al. Search-coil head-thrust and caloric tests in Ménière's disease. *Acta Otolaryngol* 2005;125(8):852–7.
45. Semaan MT, Megerian CA. Ménière's disease: a challenging and relentless disorder. *Otolaryngol Clin North Am* 2011;44(2):383–403, ix.
46. Huppert D, Strupp M, Brandt T. Long-term course of Ménière's disease revisited. *Acta Otolaryngol* 2010;130(6):644–51.
47. Thirlwall AS, Kundu S. Diuretics for Ménière's disease or syndrome. *Cochrane Database Syst Rev* 2006;(3):CD003599.
48. Strupp M, Huppert D, Frenzel C, et al. Long-term prophylactic treatment of attacks of vertigo in Ménière's disease – comparison of a high with a low dosage of betahistine in an open trial. *Acta Otolaryngol* 2008;128(5):520–4.
49. Gazquez I, Soto-Varela A, Aran I, et al. High prevalence of systemic autoimmune diseases in patients with Ménière's disease. *PLoS One* 2011;6(10):e26759.
50. Boleas-Aguirre MS, Lin FR, Della Santina CC, et al. Longitudinal results with intratympanic dexamethasone in the treatment of Ménière's disease. *Otol Neurotol* 2008;29(1):33–8.
51. Garduno-Anaya MA, Couthino De Toledo H, Hinojosa-Gonzalez R, et al. Dexamethasone inner ear perfusion by intratympanic injection in unilateral Ménière's disease: a two-year prospective, placebo-controlled, double-blind, randomized trial. *Otolaryngol Head Neck Surg* 2005;133(2):285–94.
52. Gottshall KR, Hoffer ME, Moore RJ, et al. The role of vestibular rehabilitation in the treatment of Ménière's disease. *Otolaryngol Head Neck Surg* 2005;133(3):326–8.